

8-2012

The effect of implant placement and simultaneous soft tissue augmentation in the esthetic zone using either connective tissue autograft or acellular dermal matrix allograft.

Thomas L. Peterson 1980-
University of Louisville

Follow this and additional works at: <https://ir.library.louisville.edu/etd>

Recommended Citation

Peterson, Thomas L. 1980-, "The effect of implant placement and simultaneous soft tissue augmentation in the esthetic zone using either connective tissue autograft or acellular dermal matrix allograft." (2012). *Electronic Theses and Dissertations*. Paper 1120.
<https://doi.org/10.18297/etd/1120>

This Master's Thesis is brought to you for free and open access by ThinkIR: The University of Louisville's Institutional Repository. It has been accepted for inclusion in Electronic Theses and Dissertations by an authorized administrator of ThinkIR: The University of Louisville's Institutional Repository. This title appears here courtesy of the author, who has retained all other copyrights. For more information, please contact thinkir@louisville.edu.

**THE EFFECT OF IMPLANT PLACEMENT AND SIMULTANEOUS SOFT
TISSUE AUGMENTATION IN THE ESTHETIC ZONE USING EITHER
CONNECTIVE TISSUE AUTOGRAFT OR ACELLULAR DERMAL MATRIX
ALLOGRAFT**

By

Thomas L. Peterson
D.M.D., Georgia Health Sciences University, 2009

A Thesis
Submitted to the Faculty of the
School of Dentistry at the University of Louisville
in Partial Fulfillment of the Requirements
for the Degree of

Master of Science

Program in Oral Biology
School of Dentistry
University of Louisville
Louisville, Kentucky

August, 2012

**THE EFFECT OF IMPLANT PLACEMENT AND SIMULTANEOUS SOFT
TISSUE AUGMENTATION IN THE ESTHETIC ZONE USING EITHER
CONNECTIVE TISSUE AUTOGRAFT OR ACELLULAR DERMAL MATRIX
ALLOGRAFT**

By

Thomas L. Peterson

D.M.D., Georgia Health Sciences University, 2009

A Thesis Approved on

August 3, 2012

By the following Thesis Committee:

Henry Greenwell, Thesis Director

Margaret Hill

R. Vidal

Dean Morton

DEDICATION

This thesis is dedicated to my parents who have always encouraged and supported me throughout my educational career. I would not have made it this far without their love and constant motivation. Thank you for everything that you have done and continue to do for me in my pursuit of becoming a periodontist. I would also like to dedicate this thesis to Dr. Wigand and Dr. Poulias who have been the best co-residents one could ask for.

ACKNOWLEDGEMENTS

I would like to express my sincere gratitude to the following individuals:

Dr. Henry Greenwell, Program Director of Graduate Periodontics, for your mentoring throughout my training to become a periodontist. Your daily dedication and passion to this field is inspiring. Your guidance and time in the preparation of this thesis and throughout my residency is truly appreciated. I feel very fortunate to have received my training in periodontics under such a knowledgeable and accomplished individual.

Dr. Margaret Hill, Assistant Program Director, for all your help and guidance throughout these past few years. Your insight and willingness to listen has always been appreciated. It has been a pleasure to work with you in clinic during my training in the Graduate Periodontic program.

ABSTRACT

THE EFFECT OF IMPLANT PLACEMENT AND SIMULTANEOUS SOFT TISSUE AUGMENTATION IN THE ESTHETIC ZONE USING EITHER CONNECTIVE TISSUE AUTOGRAFT OR ACELLULAR DERMAL MATRIX ALLOGRAFT

Thomas L. Peterson, DMD

August 3, 2012

Aims. The primary aims of this randomized, controlled, blinded clinical trial were to compare the hard and soft tissue response following either a connective tissue (CT) or acellular dermal matrix (ADM) graft placed simultaneously with a laser-grooved implant.

Methods. Twenty-four patients received a single tooth implant in the maxillary anterior that was bordered by two teeth. Twelve patients were randomly selected, using a coin toss, to receive either an ADM (test) or a CT (control) graft. At the 2-month uncovering appointment a lab constructed provisional was placed. At 4 months, following 2 months of tissue shaping, a fixture level impression was taken to capture the emergence profile. The final restoration was fabricated and placed. Final measurements were taken at 12 months.

Results. Soft tissue thickness at 4 months was 3.1 mm at the crest for both CT and ADM groups; although ADM showed a greater increase in thickness from implant placement.

Results. Soft tissue thickness at 4 months was 3.1 mm at the crest for both CT and ADM groups; although ADM showed a greater increase in thickness from implant placement. Facial recession at 6 months for the ADM group was 0.6 ± 0.5 mm and the CT group was 0.5 ± 0.5 mm ($p > 0.05$). Gingival margin harmony was 40% (2 of 5) for the ADM group and 50% (3 of 6) for the CT group. Using the Jemt papilla index, the ADM group had $\geq 50\%$ papilla fill in 80% of sites (8 of 10) while the CT group had 83% (10 of 12) of sites. Papilla harmony was achieved in 20% (1 of 5) of cases in the ADM group and 50% (3 of 6) for the CT group. Implant platform to osseous crest, at 6 months, for the ADM group was 0.4 ± 0.5 mm for both the mesial and distal, respectively, while the CT group was 0.5 ± 0.4 mm for the mesial and 0.5 ± 0.3 mm for the distal ($p < 0.05$). The Pink Esthetic Score was 10.9 ± 0.9 for the ADM group and 11.8 ± 1.3 for the CT group. The White Esthetic score was 8.0 ± 2.0 mm for the ADM group and 7.3 ± 1.3 mm for the CT group. Patient's subjective esthetic scores showed patients were equally satisfied with both treatment groups.

Conclusions. Facial recession and gingival margin harmony were similar for both treatment groups. Jemt papilla index scores and papilla harmony were similar for both groups. Loss of osseous crest on the mesial and distal of the implants was slightly greater for the laser group but was not statistically different from the standard group. Subjective patient assessment of esthetics using the Visual Analog Scale was similar for both groups.

TABLE OF CONTENTS

PAGE

DEDICATION	iii
ACKNOWLEDGEMENTS	iv
ABSTRACT	v
TABLE OF CONTENTS	vii
LIST OF TABLES	ix
LIST OF FIGURES	x

CHAPTER

I. LITERATURE REVIEW

Criteria for Implant Success	2
Success of Delayed Implant Placement.....	4
Soft Tissue Stability Around Implants	7
Recession	7
Anatomy and Biologic Width.....	10
Implant Design	12
Rationale for the Laser-Lok Collar Design	12
Implant Surface	13
Microgrooves.....	13
Treatment Planning	15
Presence of Papilla	15
Site Selection	27
Implant Placement	28
Incisions.....	28
Mesial-Distal Placement.....	28
Buccolingual Placement	29
Apicocoronal Placement.....	30
Platform Selection	30
Platform Switching.....	31
Provisionalization	32
Restorative Success	34
Soft Tissue Augmentation	35

II. MATERIALS AND METHODS	
Study Design	38
Inclusion Criteria	40
Exclusion Criteria	41
Post-Surgical Exclusion	41
Pre-surgical Management.....	41
Clinical Indices at the Tooth-Implant Site	41
Pre-surgical Measurements at the Tooth-Implant Site	42
Surgical treatment.....	42
Surgical measurements.....	43
Prosthetic treatment	44
Measurements for the implant at 2, 4, and 6 months	45
Restoration Form	46
Measurement Techniques	46
Statistical Analysis	46
III. RESULTS.....	47
IV. DISCUSSION	64
V. CONCLUSIONS	70
REFERENCES	73
APPENDICES	87
CURRICULUM VITAE.....	103

LIST OF TABLES

TABLE	PAGE
1. Success of Delayed Implants	5
2. Success of Maxillary Single/Multi-tooth Replacement	6
3. 1- to 5-year Recession Data	9
4. Anatomy of Teeth in the Esthetic Zone	11
5. Papilla Fill from Crown Insertion to 5 years	17
6. Horizontal and Vertical Bone to Contact Distance for Predictable Papilla	21
7. Papilla Height Relative to Periodontal Biotype	21
8. Tooth-Implant Papilla Fill Relative to Osseous Crest to Contact Distance	23
9. Papilla Fill Relative to the Tooth-Implant Horizontal Distance	24
10. Implant-Implant Papilla Fill Relative to Osseous Crest to Contact Distance	25
11. Implant-Implant Papilla Fill Relative to Horizontal Inter-implant Distance	26
12. London's Optimal Implant Diameters	31
13. Implant Placement Data	54
14. Soft Tissue Dimensions	55
15. Dimensions Related to Papilla Formation	56
16. Tissue Thickness Dimensions.....	57
17. Frequency of Papilla and Gingival Margin Harmony.....	58
18. Objective and Subjective Evaluation of Implant Esthetics.....	59
19. Jemt Papilla Index Stratified by Amount of Vertical Fill	60
20. Clinical Indices	61
21. Adjacent Tooth Bone Loss.....	62
22. Radiographic Implant Platform to Interproximal Osseous Crest.....	63

LIST OF FIGURES

FIGURE	PAGE
1. Study Design.....	40
2. ADM Pre- and Post-op Views	71
3. CT Pre- and Post-op Views	72

CHAPTER I

LITERATURE REVIEW

In contemporary dentistry, dental implants have become the standard of care to replace missing teeth. Grutter and Belser (2009) conducted a comprehensive search pertaining to immediate restored or conventional loaded implants in the esthetic zone. Analysis of 1,922 implants revealed a 1-year survival rate of 97.3%, and a 1-5 year survival rate of 96%. The osseointegration of dental implants has become a predictable procedure, but an implant that is osseointegrated does not always translate to esthetic success. As implant survival and success rates remain high, the aesthetic outcomes have become the focus of attention of both patients and clinicians.

Ultimately, the maxillary anterior presents as the most challenging region to meet these aesthetic demands. A major concern from an esthetic standpoint is peri-implant soft tissue recession occurring both facially and interproximally. Gingival recession is the most common complication of single tooth implants (Goodacre et al. 1999). There are multiple contributing factors that play a role in achieving optimal esthetics: implant position and inclination, gingival biotype, gingival contour, facial bone thickness and height, osseous scallop, interproximal bone level, and restoration form and emergence. It is because of these numerous factors that great emphasis has been placed on the relationship of these parameters to peri-implant gingival esthetics. Understanding these

factors is paramount in preventing gingival recession and interproximal papilla loss and avoiding complications leading to unesthetic outcomes.

Criteria for Implant Success

Albrektsson (1986) developed criteria for implant success that have become the standard to which implant success is determined and is stated as follows:

1. That an individual, unattached implant is immobile when tested clinically.
2. That a radiograph does not demonstrate any evidence of peri-implant radiolucency.
3. That vertical bone loss is less than 0.2 mm annually following the first year of service.
4. That individual implant performance be characterized by an absence of persistent and/or irreversible signs and symptoms such as pain, infection, neuropathies, paresthesias, or violation of the mandibular canal.
5. That, in the context of the above, a successful rate of 85% at the end of a 5-year observation period and 80% at the end of a 10 year period be a minimum criteria for success.

This was modified by Roos et al. (1997) to include different grades of success for implants. The new classification is as follows:

Grade 1:

1. Absence of mobility is checked by individual testing of the unattached implant, using a light tightening force of an abutment screwdriver without simultaneous counteracting of the force via an abutment clamp.

Any mobility or sensation/pain from the anchorage unit is regarded as a sign of lost osseointegration.

2. Radiographic evaluation of each implant reveals not more than 1.0 mm of marginal bone loss during the first year of loading, followed by not more than 0.2 mm resorption per year, as well as absence of peri-implant pathosis, such as a peri-implant radiolucency.
3. Severe soft tissue infections, persistent pain, paresthesia, discomfort, etc, are absent.

Grade 2:

1. Radiographic evaluation of each implant reveals not more than 1.0 mm of marginal bone loss during the first year of loading, followed by not more than 0.2 mm resorption per year, as well as absence of peri-implant pathosis, such as a peri-implant radiolucency.
2. Severe soft tissue infections, persistent pain, paresthesia, discomfort, etc, are absent.

Grade 3:

1. Radiographic evaluation of each implant reveals not more than 0.2 mm of marginal bone resorption during the last year, but previously more than 1.0 mm of bone loss has taken place. Peri-implant pathosis, such as a peri-implant radiolucency is absent.
2. Severe soft tissue infections, persistent pain, paresthesia, discomfort, etc, are absent.

Smith and Zarb (1989) proposed the following criteria for implant success:

1. The individual unattached implant is immobile when tested clinically.
2. No evidence of peri-implant radiolucency is present as assessed on an undistorted radiograph.
3. The mean vertical bone loss is less than 0.2 mm annually after the first year of service.
4. No persistent pain, discomfort, or infection is attributable to the implant.
5. The implant design does not preclude placement of a crown or prosthesis with an appearance that is satisfactory to the patient and dentist.
6. By these criteria, a success rate of 85% at the end of a 5-year observation period and 80% at the end of a 10-year period are minimum levels for success.

Buser et al. (1990) proposed the following criteria for implant success:

1. Absence of persistent subjective complaints, such as pain, foreign body sensation and/or dysaesthesia.
2. Absence of a recurrent peri-implant infection with suppuration
3. Absence of mobility
4. Absence of a continuous radiolucency around the implant
5. Possibility for restoration.

Success of Delayed Implant Placement

Studies have demonstrated that implant therapy is predictable and successful.

Table 1 shows implant success rates to be approximately 93% and survival 96%.

Table 1
Success of Delayed Implants

Author	Term (yrs)	Mean (yrs)	Implant	Pts	N impl	Success %	Max.	Mand.	Survival %
Wheeler 1996	8.0	8.0	TPS	479	891		80.6	96.2	92.7
Wheeler 1996	8.0	8.0	HA		313		74.1	80.5	77.8
Buser et al. 1997	8.0	8.0	ITI	1003	2359	93.3	87.3	94.8	96.7
Rosenberg et al. 1998	7.5	7.0	Multiple	322	958	93.00			
Wyatt and Zarb 1998	1 to 12	5.0	Branemark	77	230	94.00			
Grunder et al. 1999	3.0	3.0	Multiple	143	264	93.30	92.40	94.70	
Morris and Ochi 2000	3 to 5	4.0	Spectra	829	2998				92.1
van Steenberghe et al. 2000	2.0	2.0	Multiple	18	95	98.9			
Zitzmann et al. 2001	5.0	5.0	Branemark	75	153				95.8
Davarpanah et al. 2002	1 to 5	3.0	3i	528	1583	96.50	97.20	95.80	
Naert et al. 2002	16.0	16.0	Branemark	660	1956	91.40			
Aalam and Nowazari 2005	2.0	2.0	Multiple	74	198	100	100	100	
Degidi et al. 2006	1.0	1.0	Friadent	321	802	91.4	91.2	91.6	99.6
Khayat and Milliez 2007	2.0	2.0	Zimmer	328	835	98.6	98.6	98.8	99.4
Raes et al. 2011	1.0	1.0	Astra	23	23		100		100
deBruyn et al. 2011	3.0	3.0	Nobel	49	53	80			100
Patel et al. 2012	1.0	1.0	Straumann TL	27	27	84			100
Penarrocha-Oltra et al. 2012	1.0	1.0	Impladent		88	93	93		96
Mean		4.4		310	768	93	91	94	96

Maxillary anterior tooth replacements have a success and survival rates of approximately 96 and 98% respectively (Table 2).

Table 2

Success of Maxillary Anterior Single/Multi-tooth Replacement

Author	Term (yrs)	Mean (yrs)	Implant	N impl	Success	Survival
Jemt et al. 1991	1.0	1.0	Branemark	107		97.2
Andersson et al. 1993	2 to 4	3	Branemark	102		98.0
Jemt and Petterson 1993	3.0	3.0	Branemark	70		98.6
Schmitt and Zarb 1993	1.4 to 6.6	4.0	Branemark	27	100.0	
Ekfeldt et al. 1994	1 to 3	2.0	Branemark	93		97.8
Laney et al. 1994	3.0	3.0	Branemark	95		97.2
Andersson et al. 1995	3 year	3.0	Branemark	65		97.3
Engquist et al. 1995	1 to 5	3.0	Branemark	82		97.6
Avivi-Arber and Zarb 1996	1 to 8	4.0	Branemark	49	84	98
Henry et al. 1996	5.0	5.0	Branemark	71	96.6	
Melevez et al. 1996	5	5.0	Branemark	84		97.7
Walther et al. 1996	10.0	10.0	Branemark	236	89.0	
Karlsson et al. 1997	2	2.0	Astra	47		100
Kempainen et al. 1997	1.0	1.0	Astra	46	97.8	
Kempainen et al. 1997	1.0	1.0	ITI	56	100.0	
Levine et al. 1997	6 month	0.5	ITI	174	97.7	100
Norton 1997	6	6.0	Astra	27		100
Palmer et al. 1997	2	2.0	Astra	15		100
Scheller et al. 1998	1 to 5	3.0	Branemark	99	95.9	98
Levine et al. 1999	2	2.0	ITI	174		95.5
Moberg et al. 1999	3 to 4	3.0	ITI	30		96.7
Priest 1999	10	10.0	Branemark	116		97.4
Scholander 1999	1 to 9	5.0	Branemark	259	98.3	98.5
Thilander et al. 1999	8	8.0	Branemark	15		100
Palmer et al. 2000	5.0	5.0	Astra	15	100.0	
Haas et al. 2002	10.0	10.0	Branemark	76		93
Romeo et al. 2002	7.0	7.0	ITI	187	96.2	99.35
Palmer et al. 2003	2.5	2.0	Astra	15	100.0	
Levin et al., 2005	1 to 9	5.0	Multiple	52	92.6	
Schropp et al. 2005b	2.0	2.0	3i	46	93.5	
Buser et al 2008	2 to 5	3.0	Straumann	45	100.0	
Schropp et al. 2008	5.0	5.0	3i	22		95
Ribeiro 2008	1.5 to 3.3	2.0	Multiple	36	100	
Cooper 2008	3	3.0	Astra	54		94
Belser et al. 2008	2-4		Straumann	45	100	100
Valentini et al. 2010	1	1.0	Astra	43		95
Cosyn et al. 2011	3	3.0	Nobel Repl	25		96
Kan et al. 2011	4	4.0	Nobel Repl	35	100.0	96
Koh et al. 2011	4	0.3	Laser Lok	24		
Raes et al. 2011	1	1.0	Astra	16		94.0
Raes et al. 2011	1	1.0	Astra	23		100
Buser et al. 2011	3	3.0	Straumann	20	100.0	100
Chung et al. 2011	1	1.0	3i Osseotite	10	90.0	
Lops et al. 2011	1	1.0	Astra	25		100
Lops et al. 2011	1	1.0	Straumann	25		100
Mean		3.5		67.7	96.3	97.7

Soft Tissue Stability Around Implants

Recession. A major concern from the esthetic point of view is peri-implant soft tissue recession occurring facially and interproximally. Previous studies have shown that facial marginal mucosal level are affected by multiple factors including the peri-implant biotype, facial and interproximal and crestal bone levels, implant fixture level, and implant position and inclination. Evans and Chen (2008) reported a mean facial recession of 0.5-1 mm around single-tooth implants. According to Jemt et al. (2006) facial recession of 1mm or more was observed in 17- 40% of the study subjects.

Kan et al. (2011) showed that sites with thicker gingival biotypes demonstrated statistically significantly smaller changes in facial gingival levels than sites with thinner gingival biotypes at time of implant placement (-0.25 mm versus -0.75 mm respectively) and at mean 4-year follow up (-0.56 mm versus -1.50 mm respectively). Another study conducted by Zigdon et al. (2008) evaluated 63 implants in 32 patients and concluded a wider mucosal band (> 1 mm) was associated with less marginal recession compared to a narrow (less than equal to 1 mm) band (0.27 and 0.29 mm, p=0.001). A thick mucosa (greater than or equal to 1 mm) was associated with less recession compared with a thin (< 1 mm) mucosa (0.45 and 0.9 mm, p=0.04).

Kan et al. (2009) reported that enhancement of gingival thickness through connective tissue augmentation at time of implant placement made gingival tissues more resistant to recession. Thick tissue showed a gain of 0.23 mm while thin tissue showed a gain of 0.06 mm. Kim et al. (2009) found more recession with the deficient keratinized

tissue (≤ 2 mm) than sufficient keratinized tissue (> 2 mm) and reported recession of 0.72 vs. 0.32 mm, respectively.

Implant placement can be performed by either an immediate or delayed approach and by means of a flap or flapless approach. Studies have shown conflicting results; especially in regard to tissue recession associated with immediately placed implants. In a study conducted by Raes et al. (2011), immediate and delayed single implants in the maxillary anterior were compared. At 1 year, immediate vs. delayed showed a mean mid-facial recession of (-0.12 vs. -1.00 mm). Advanced midfacial recession exceeding 1 mm was found in 7% of immediately installed implants and 43% of delayed implants. Immediate implants installed with a flapless approach showed significantly less midfacial recession when compared with a flap procedure at 1 year (mean difference 0.89 mm). Recession data from previous studies is reported in Table 3.

Table 3

1- to 5-year Facial Recession Data

Study	Year	Implants	1 yr	1.5-2.0 yrs	3-5 yrs
Bengazi et al.	1996	158		0.50	
Bengazi et al.	1996	158		0.60	
Grunder	2000	10	0.60		
Small and Tarnow	2000	63	0.88		
Small et al.	2001	150			0.73
Small et al.	2001	62			1.58
Zitzmann et al.	2001	112	0.06		0.01
Oates et al.	2002	106	0.70	0.90	
Giannopoulou et al.	2003	61	-0.20		-0.30
Kan et al.	2003	35	0.55		
Priest	2003	55	0.13		0.06
Gotfredsen	2004	10			0.30
Gotfredsen	2004	10			-0.30
Cardaropoli et al.	2006	11	0.60		
Weber et al.	2006	59	0.28		0.30
Weber et al.	2006	93	-0.04		-0.02
Canullo and Rasperini	2007	10	-0.20		
Cooper et al.	2007	43	-0.34		-0.51
Hall et al.	2007	14	0.67		
Hall et al.	2007	14	0.33		
Evans and Chen	2008	42		0.90	
Palattella et al.	2008	9	0.60		
Palattella et al.	2008	9	0.80		
Zigdon and Machtei	2008	22	0.90		0.90
Zigdon and Machtei	2008	41	0.45		0.27
Zigdon and Machtei	2008	25	0.27		0.90
Zigdon and Machtei	2008	38	0.90		0.45
Kan et al.	2009	12		-0.06	
Kan et al.	2009	8		-0.23	
Kim et al.	2009	90	0.72		
Kim et al.	2009	186	0.32		
DeRouck et al.	2009	25	0.41		
DeRouck et al.	2009	24	1.16		
Nisapakuhorn et al.	2010	40	0.50		
Raes et al.	2011	39	1.00		
Raes et al.	2011	39	0.12		
Kan et al.	2011	14	0.25		0.56
Kan et al.	2011	21	0.75		1.50
Gallucci et al.	2011	10	0.85	0.96	
Gallucci et al.	2011	10	0.60	0.50	
Chung et al.	2011	10	0.05		
Cosyn et al.	2011	28	0.53		
Cosyn et al.	2011	25			0.34
Mean ± sd		46 ± 46	0.5 ± 0.4	0.5 ± 0.5	0.4 ± 0.6
n		43.0	33.0	8.0	17.0

Anatomy and Biologic Width. Ochsenbein and Ross (1969) described two main types of gingival morphology, the scalloped and thin or flat and thick gingival. They proposed that the contour of the gingiva closely followed the contour of the underlying bone. The more prevalent, thick flat type occurs in over 85% of the patient population; while the other 15% display a thin, scalloped type. Later, Seibert and Lindhe (1989) observed that a thick-flat periodontal biotype was associated with quadratic teeth and wide zones of keratinized tissue. On the other hand, a thin-scalloped periodontal biotype was associated with slender teeth, which presented with narrow zones of keratinized tissue. Becker (1997) evaluated 111 dry skulls and divided them into 3 groups: flat, scalloped, and pronounced scalloped anatomic profiles according to the alveolar bone anatomy. Measurements were made with a probe from the height of the interproximal bone to the buccal alveolar crest. The mean distance from the height of the interdental bone to the alveolar crest was statistically significant when the groups were compared (flat 2.1 mm, scalloped 2.8 mm, pronounced 4.1 mm). The degree of scallop is of importance in implant dentistry because of the morphologic changes which occur following tooth extraction. A thick, flat site may show insignificant subtle changes following extraction, while a thin, scalloped biotype may lead to significant soft and hard tissue alterations following extraction. The thin, scalloped biotype usually presents with thin facial bone and fenestrations or dehiscences are commonly found.

A normal, healthy periodontium is characterized by a rise and fall of the facial gingival margin and interproximal papillary height. This results in the location of the gingival margin more apical on the direct facial and more incisal at the interproximal

regions. According to Sanavi et al. (1998) in the healthy periodontium, the underlying bony crest lies approximately 2 mm apical to the cemento enamel junctions (CEJ) and follows the configuration of the CEJ on all four surfaces of the tooth. Wheeler's text identifies mean dimensions of teeth and curvature of the cemento enamel junction.

Table 4

Anatomy of Teeth in the Esthetic Zone

	Crown length	M-D Crown Width	M-D Diameter at CEJ	B-L Diameter	B-L Diameter at CEJ	Curvature of CEJ on M	Curvature of CEJ on D
Central	10.5	8.5	7.0	7.0	6.0	3.5	2.5
Lateral	9.0	6.5	5.0	6.0	5.0	3.0	2.0
Canine	10.0	7.5	5.5	8.0	7.0	2.5	1.5
1 st premolar	8.5	7.0	5.0	9.0	8.0	1.0	0.0
2 nd premolar	8.5	7.0	5.0	9.0	8.0	1.0	0.0

*Adapted from text by Wheeler

The biologic width around both teeth and implants is of utmost importance when placing implants in the esthetic zone. Cohen (1962) coined the term biologic width to describe the combined 2.04 mm dimension of the connective tissue and the epithelial attachment. The preparation and restoration of a tooth that violates the epithelial and connective tissue attachment usually results in a poor gingival response. Gargiulo et al. (1961) measured the dimension of attachment apparatus in human autopsy material. He concluded that biologic width consists of a mean of 1.07 mm connective tissue, a mean of 0.97 mm epithelial attachment, and a mean sulcus depth of 0.69 mm. The structure of the soft tissues surrounding implants is, in many ways, analogous to the natural dentition. In

studying the biologic width around implants, Cochran et al. (1997) determined that after 12 months of functional load of implants in foxhounds, biologic width consists of a mean of 1.05 mm connective tissue, 1.88 mm epithelial attachment, and 0.16 mm sulcus depth. Romanos et al. (2010) studied biologic width around 12 immediately loaded implants in a human autopsy specimen after 7 months of loading. The sulcus + biologic width in the maxilla was 6.5 ± 2.5 mm, whereas in the mandible, it was 4.8 ± 1.3 mm. The junctional epithelium (JE) in the maxilla was 1.3 ± 0.4 mm and 1.5 ± 0.5 mm in the mandible. The connective tissue (CT) in the maxilla was 2.5 ± 1.3 mm, whereas in the mandible, it was 1.6 ± 0.4 mm.

Implant Design

Rationale for the LaserLok Collar Design. Laser-Lok microchannels (BioHorizons) are formed by a computer-controlled laser ablation technique that creates a series of microgrooved surfaces to optimally control the orientation of attached cells. The collar consists of both 8 and 12 micron grooves that are engineered to maintain and prevent crestal bone loss, inhibit epithelial downgrowth, and provide for connective tissue attachment.

Biohorizon's standard implant traditionally had a 1.8 mm polished collar. This collar was replaced with the 8 and 12 micron grooves that have been shown to provide soft tissue and bone attachment, thereby preventing soft and hard tissue loss. The coronal 0.3 mm was a machined surface. The next 0.7 mm wide zone of 8 micron cell channels provides an epithelial barrier and CT attachment. The final 0.8 mm wide zone of 12 micron cell channels promotes bone formation (Brunette et al. 1999). In January of 2011,

the latest change was made which features a full 1.8 mm Laser-Lok collar (no smooth, machined area).

Implant Surface. The tapered internal hex implants are manufactured with a resorbable blast textured (RBT) surface and Laser-Lok micron sized channels at the implant neck. The (RBT) surface is a roughened surface designed to increase biological fixation and to maximize implant-to-bone contact. In 1997 BioHorizons pioneered the use of (RBT) and it has been shown to improve bone cell contact as compared to machined titanium surfaces. The calcium phosphate used to blast the surface is biocompatible and resorbs during the passivation process leaving the optimum roughness profile of a pure TiO₂ surface.

Microgrooves. Weiner et al. (2008) studied the effects of microgrooved surfaces with groove widths and depths in the range of 6 to 12 microns. Specifically, 12 micron grooves showed the best potential for inhibition of fibrous tissue growth relative to bone cell growth, and 8 micron grooves showed the most effective inhibition of epithelial cell migration across the grooves. When compared with machined collars, the laser collar had less soft tissue downgrowth, less osteoclastic activity, and decreased saucerization.

Nevins et al. (2008) conducted a human histologic study to evaluate the connective tissue potential to attach to Laser-Lok surface. Results showed that between the apical termination of the junctional epithelium and the alveolar bone crest, connective tissue in direct apposition to the implant surface. Light microscope evaluation revealed the microgrooved area of the implants was covered with connective tissue. Polarized light microscopy of this area revealed functionally oriented collagen fibers running toward the grooves of the implant. Scanning electron microscopy confirmed the presence

of attached collagen fibers. It was concluded that this attachment is instrumental in preserving the alveolar bone crest and inhibiting apical migration of the epithelium.

Botos et al. (2011) evaluated the effects of laser microtexturing on the implant collar on crestal bone levels and peri-implant health. Two Laser-Lok implants were compared to two Nobel Replace Select implants in the mandibular anterior. Results at both 6 and 12 months showed shallower pocket depths (PD) and less peri-implant crestal bone loss with the Laser-Lok implants.

Recently, scanning electron microscopy (SEM) has revealed that there is not much difference between 8 and 12 micron grooves in gaining soft/hard tissue attachment. These findings lead to the manufacturing of tapered internal implants with Laser-Lok (TLX) which have a 1.8 mm laser micromachined surface consisting of 8 micron grooves the entire length (BioHorizons, Inc. personal communication).

Abutment Design

Rationale for Laser Microgrooved Abutments. Nevins et al. (2010) compared bone and soft tissue healing patterns when laser-ablated microgrooves are placed on the abutment versus standard machined surfaces in canines. Results showed that the presence of the 0.7 mm laser ablated microchanneled zone consistently enabled intense fibroblastic activity to occur on the abutment-grooved surface, resulting in a dense complex of connective tissue fibers oriented perpendicular to the abutment surface. It was concluded that the inhibition of the apical migration of junctional epithelium (JE) prevented crestal bone resorption. Two cases showed bone regeneration coronal to the implant-abutment junction (IAJ) and onto the abutment surface. Nevins et al. (2012) conducted a human histologic study to assess CT attachment to laser-microgrooved

abutments. Results showed the laser-ablated microgrooves allowed direct CT attachment to the altered abutment surface, prevented apical migration of the junctional epithelium, and thus protected the crestal bone from premature resorption.

Treatment Planning

Presence of Papilla. Jemt (1997) created an index to assess the size of the interproximal gingival papillae adjacent to single implant restorations. The results of the study indicated a spontaneous regeneration of papilla ($P < .001$) after a mean follow-up period of 1.5 years. Based on these findings, the general conclusion was made that the proposed index allows scientific assessment of soft tissue contour adjacent to single-implant restorations.

Index score 0: No papilla is present, and there is no indication of a curvature of the soft tissue contour adjacent to the single-implant restoration.

Index score 1: Less than half of the height of the papilla is present. A convex curvature of the soft tissue contour adjacent to the single implant crown and the adjacent tooth is observed.

Index score 2: At least half of the height of the papilla is present, but not all the way up to the contact point between the teeth. Papilla is not completely in harmony with the adjacent papillae between the permanent teeth.

Index score 3: The papilla fills up the entire proximal space and is in good harmony with the adjacent papillae. There is optimal soft tissue contour.

Index score 4: The papillae are hyperplastic and cover too much of the single implant restoration and/or the adjacent tooth. The soft tissue contour is more or less irregular.

Table 5 below includes the papilla fill results from various studies ranging from 6 months to 3-5 years post crown delivery.

Table 5

Papilla Fill from Insertion to 5 years

Study	Crown Insertion (6 mo)			1-2 year			3-5 year		
	Comp	≥ 50%	≤ 50%	Comp	≥ 50%	≤ 50%	Comp	≥ 50%	≤ 50%
Jemt 1997	10	50	50	60	90	10			
Jemt 1999	13	83	17	40	93	7			
Chang et al. 1999	4	54	46				46	92	8
Nemcovsky et. Al 2000	32	85	15						
Choquet et al. 2001							58	89	11
Schropp et al. 2005, 2008	11	52	48	9	69	31	39	83	17
Schropp et al. 2005, 2008	16	58	42	32	88	12	46	78	22
Cardaropoli et al. 2006	9	32	68	18	86	14			
Kan 2007	46	92	8						
Kan 2007	73	98	2						
Hall et al. 2007	18	64	36	31	82	18			
Degidi et al 2008	23	90	10	22	93	7	36	86	14
Palattella 2008				39	83	17			
Palattella 2008				50	89	11			
Kan et al. 2009	88	100	0	71	100	0			
Kan et al. 2009	88	100	0	94	100	0			
Nisapakuhorn et al. 2010				36	53	11			
Raes et al. 2011				59	59	41			
Raes et al. 2011				53	53	47			
Chung et al. 2011				78	89	11			
Cosyn et al. 2011							52	52	48
Mean ± sd	33 ± 13	74 ± 13	26 ± 13	46 ± 15	82 ± 15	16 ± 15	46 ± 6	80 ± 6	20 ± 6

The interdental papillae are of special esthetic significance since they are usually visible in a smile. A normal interdental papilla fills the embrasure space to the contact point and any deviation will cause the appearance of a “black triangle” which is an esthetic deficiency. Factors such as crestal bone height, interproximal distance, tooth form/shape, gingival thickness, and keratinized tissue width have been identified to influence the appearance of the interimplant papillae (Chow and Wang 2010). Obtaining this papilla fill following implant crown placement remains a challenging problem in implant dentistry.

Jemt (1997) conducted a study to evaluate healing following implant placement and provisionalization. The results showed that on average about half of the height of the papilla was lost (mean index 1.5) when the soft tissue was allowed to heal completely around the temporary abutment prior to crown fabrication. At 1-3 year follow-up, spontaneous regeneration was observed with 58% of the papillae completely recovered and in harmony with the adjacent teeth. Chang et al. (1999) evaluated soft tissue healing after single-tooth replacement in the maxillary esthetic zone in 20 patients. At crown placement 4% had complete papilla fill and at 38-month follow-up this increased to 46%. Papilla fill $\geq 50\%$ increased from 54% at crown placement to 92% at 38-month follow-up. Choquet et al. (2001) studied the papilla level around single dental implants placed in 26 patients in the maxillary anterior. At a mean follow-up of 35 months, 58% of papilla had complete fill, 89% had $\geq 50\%$ papilla fill, and 11% had $< 50\%$ papilla fill.

Schropp et al. (2008) evaluated soft tissue changes after implants were placed in either an early (mean 10 day post extraction) or delayed (3 months after extraction) approach. At baseline measures 19% of the papilla in the delayed group were lacking

(score 0) versus 9% in the early group. During the 5-year follow-up period a continuous improvement in papilla height was observed and no significant differences were found between groups.

Raes et al. (2011) conducted a study to compare soft tissue dynamics following the placement of 16 immediate and 23 delayed single implants in the maxillary anterior. At 1 year follow-up, the authors observed that 59% of the delayed implants had complete papilla fill compared to 53% in the immediate group. Significant distal papilla loss (-0.38 mm) was noted in the immediate group.

Cosyn et al. (2011) evaluated the hard and soft tissue response of 25 immediately placed single-tooth implants placed in the maxillary anterior. At 3-year follow-up 52% of sites showed complete papilla fill. Mean mesial/distal papilla shrinkage in reference to pre-operative status accounted for 0.05 and 0.08 mm. Between 1- and 3-year reassessment the mesial /distal papilla growth was 0.36 mm and 0.23 mm.

Kan et al. (2011) evaluated the gingival tissue stability following immediate placement and provisionalization of 35 maxillary anterior implants with a mean follow-up of 4 years. The results show at time 3 (mean 4 years) that the benefits of flapless immediate implant placement can be demonstrated by the mean overall mesial papilla level and distal papilla level changes (-0.22 mm and -0.21 mm, respectively). These changes at time 3 were significantly smaller than those changes (-0.53 mm and -0.39 mm) seen at time 2 (1 year), which is in agreement with other studies reporting spontaneous papilla regeneration. Specifically, he compared papilla level changes in both thick and thin gingival biotypes. There was no significant differences in papilla levels between thick and thin gingival biotypes. Results also showed that the effect of

gingival biotype on peri-implant tissue response seemed to be limited only to the facial recession and did not influence interproximal papilla.

Kan et al. (2009) evaluated soft tissue changes following the placement of 20 immediate implants in the maxillary esthetic zone with a simultaneous connective tissue (CT) graft. 12 patients presented with a thin biotype, while 8 had a thick biotype. At the mean follow-up of 2.15 years all patients exhibited a thick biotype. 100% of the sites had $\geq 50\%$ papilla fill while 80% of the sites had complete papilla fill. The authors concluded that the similar results observed for both thick and thin gingival biotypes in the study suggest that the role of gingival biotype in papilla loss is minimal as long as the papilla is supported immediately after tooth removal.

Chung et al. (2011) also evaluated immediate single tooth implant placement and provisionalization with subepithelial connective tissue grafts in 10 patients. At 1-year follow-up, more than 50% of the papilla was observed in 89% of the sites, while 78% had complete papilla fill. Tsuda et al. (2011) evaluated peri-implant tissue response following connective tissue and bone grafting in conjunction with immediate single-tooth replacement in the esthetic zone. Papilla index scores (PIS) at 1-year follow-up revealed $\geq 50\%$ of papilla fill was observed in 80% of all sites. There were no statistically significant differences in the (PIS) at different time intervals (0, 3, 6, 12 months) even when necrosis of the connective tissue graft occurred in 2/10 patients. This validated previous thoughts that peri-implant papilla levels are dictated by the proximal bone levels of the adjacent teeth and that the best way to maintain the papilla is to provide hard tissue support immediately after tooth extraction.

Salama and Garber (1998) presented prognostic criteria that emphasized the osseous-gingival relationship to achieve predictable esthetic results in the anterior region. They reported the necessary horizontal and vertical interproximal dimensions to obtain papilla formation under a variety of tooth, implant, or pontic relationships (Table 6).

Table 6

Horizontal and Vertical Bone Distance for Predictable Papilla Formation

Restorative Environment	Horizontal Distance	Vertical Crest to Contact Distance
		mean
Tooth - Tooth	1 mm	5.0
Tooth - Pontic		6.5
Pontic - Pontic		6.0
Tooth - Implant	1.5 mm	4.5
Implant - Pontic		5.5
Implant - Implant	3 mm	4.5

Kan et al. (2003) evaluated the soft tissue dimensions of 45 implants placed in the maxillary anterior and compared thick and thin biotypes. He concluded that the level of the interproximal papilla is independent of the proximal bone level next to the implant, but is related to the interproximal bone level next to the adjacent teeth. Table 7 below compares papilla heights between thick and thin biotypes at 1-year.

Table 7

Papilla Height Relative to Periodontal Biotype

Kan et al. 2003	Mesial	Distal
Mean papilla height	4.2 mm	4.2 mm
Thick Biotype	4.5 mm	4.5 mm
Thin Biotype	3.8 mm	3.8 mm

In a classic study, Tarnow et al. (1992) investigated the effects of crestal bone height on the presence or absence of dental papilla between teeth. The authors examined 288 interproximal sites and demonstrated that the papilla was present almost 100% of the time when the distance from the contact point to the crest of the bone was 5 mm or less. When the distance was 6 mm, the papilla was present 56% of the time, and when the distance was 7 mm or more, the papilla was present 27 % of the time.

Grunder (2000) found similar results in a case report of 10 single implants in the maxillary anterior. Results at 1-year after function showed all peri-implant papillae reformed when the crestal bone level on the adjacent tooth was 5 mm or less from the contact. Another study conducted by Choquet et al. (2001) reported that the papilla was present almost 100% of the time when the distance from the contact point to the crest of the bone was 5 mm or less between tooth and implant. The occurrence of papilla regeneration was at least 50% of the time when the distance was ≥ 6 mm. Gastaldo et al. (2004) found that the ideal distance from the bone crest to the base of the contact between a tooth and implant should be 3-5 mm.

Regeneration of papilla between 2 implants is even more challenging than a single dental implant. Tarnow et al. (2003) investigated a total of 136 interimplant papillary heights in 33 patients and found the mean height was only 3.4 mm. Although there was a range of 1 to 7 mm, the soft tissue heights were 2, 3, or 4 mm in 90% of the cases. It was concluded that the ideal distance from the base of contact to bone crest between implants is 3 mm.

Table 8 below includes several studies that present papilla fill in relation to the distance from crest to contact point.

Table 8

Tooth-Implant Papilla Fill Relative to Osseous Crest to Contact Distance

Tooth-Implant	Choquet et al. 2001	Gastaldo et al. 2004	Ryser et al. 2005	Lops et al. 2008	Romeo et al. 2008	Digidi et al. 2008	Kawai, Almeida 2008	Mean	n
Time	1 year	1.5-6 years	2 year	1 year	1 year	3 - 5 year	>4 months		
Mean Time	1	4	2	1	1	4	0.5	1.9	7
Crest to contact (mm)									
<5	100	100	100		67	92	92	91.8	6
≤5	100	100		80				93.3	3
5	88	80	88			93	77	85.2	5
5 to 7					67			67.0	1
6	50	40	85			91		66.5	4
6+				52			75	63.5	2
7	75	40	91		33	89		65.6	5
7+				58	33			45.5	2
8	50	40	75			50		53.8	4
9	50		100					75.0	2
10+	75	25	0					33.3	3

The horizontal distance between teeth and implants is another factor which can influence papillae fill. Cho et al. (2006) evaluated 206 dental papillae in 80 patients to see correlation between interproximal distance between roots and papilla fill. The result showed an ideal horizontal distance of 1.5-2.5 mm between adjacent roots. These findings lead researchers to investigate the significance of horizontal dimensions in implants. Kawai (2008) found that 80.8% of papilla completely filled the interproximal space between tooth and implant when the horizontal distance was between 1 and 2 mm; whereas, a distance of 2 to 3 mm resulted in 58.3% papilla fill. These findings disagree with Gastaldo et al. (2004), who reported that horizontal distances smaller than 3 mm caused an absence of papilla.

Table 9

Papilla Fill Relative to the Tooth-Implant Horizontal Distance

Tooth-Implant	Gastaldo et al. 2004	Lops et al. 2008	Romeo et al. 2008	Kawai, Almeida 2008	Mean	n
Time	1.5 to 6 years	1 year	1 year	>4 months		
Mean Time	4	1	1	0.5	1.6	4
Implant to tooth distance						
0 to 1 mm				100	100.0	1
1 to 2.5		32	35.7		33.9	2
2	0			80.8	40.4	2
2.5	0				0.0	1
3	88			58	73.0	2
3 to 4		84.2	77.7	50	70.6	3
3.5	83				83.0	1
4	75			50	62.5	2
>4		70	57.1		63.6	2
4.5	56				56.0	1
5 to 6				0	0.0	1
6+				2.2	2.2	1

Tarnow et al. (2000) conducted a study to assess the horizontal component of adjacent implants and its effect on interproximal bone loss. The authors found that there was a horizontal component of bone loss around implants, and 3 mm was a critical interimplant distance. An interimplant distance > 3 mm correlated to 0.45 mm of crestal bone loss; whereas, a distance < 3 mm correlated to 1.04 mm. They concluded that this additional bone loss created a greater distance from contact to bone crest, thus affecting the presence or absence of papilla. Lee et al. (2006) also examined papilla height between implants. Results showed that if the horizontal distance between implants was < 3 mm then the mean papilla height was 3 mm or less. When the implants were ≥ 3 mm

apart the mean papilla height was 3 mm or greater. Gastaldo et al. (2004) conducted a study to evaluate the effects of vertical and horizontal distances between adjacent implants and implants and teeth on interproximal papilla. They concluded that the ideal lateral implant-tooth spacing is 3-4 mm. The results also showed an interaction between horizontal and vertical distances when the lateral spacing was greater than 3 mm. Tables 9 and 10 below report the percent of sites with $\geq 50\%$ papilla fill with varying alveolar crest to contact distance (Table 9) as well as the percent of sites with $\geq 50\%$ papilla fill with varying horizontal distances between 2 implants (Table 10).

Table 10

Implant-Implant Papilla Fill Relative to Osseous Crest to Contact Distance

Implant-Implant	Gastaldo et al. 2004	Degidi et al. 2008	Mean	n
Time	1.5 – 6 years	2 years		
Mean Time	4	2	3	2
Crest to contact (mm)				
≤ 3	100	94	97.0	2
4	50	91	70.5	2
5	40	80	60.0	2
6	26	79	52.5	2
> 6		75	75.0	1
7	40		40.0	1
8	40		40.0	1
10	25		25.0	1

Table 11

Implant-Implant Papilla Fill Relative to Horizontal Inter-implant Distance

Implant-Implant	Gastaldo et al. 2004
Time	1.5 - 6 years
Implant to implant distance	
2	0
2.5	0
3	82
3.5	81
4	71
4.5	48

Tooth shape and form can influence gingival morphology. Tooth shape can be classified into triangular, ovoid, and square while tooth form can be defined as long narrow or short wide. Olsson and Lindhe (1991) studied 192 subjects and found that patients with long-narrow/triangular-shaped upper central incisors experienced more recession mid-buccally than those with a short-wide form/square shape. Olsson et al. (1993) concluded that individuals with the long narrow tooth form displayed a thin free gingival, a narrow zone of keratinized tissue, shallow probing depth, and a pronounced scalloped contour of the gingival margin. According to Kois (2001) tooth shape is one of the five diagnostic keys in predictable single tooth peri-implant esthetics and should be considered in the presurgical phase of implant therapy. In his opinion, shape/form impacts the tissue both coronal and apical to the free gingival margin. Coronal to the FGM, individuals with square shaped teeth have a more favorable esthetic outcome because of the long proximal contact and less amount of papilla tissue to fill the interproximal space. On the other hand, the contact of triangular tooth shape is short and more incisally positioned requiring more tissue height to fill. Therefore, peri-implant

papilla regeneration can be very challenging due to the higher risk of “black triangles.” The author suggests modification of the adjacent tooth shape with either direct composite or porcelain veneer after an implant-supported restoration. Apical to the FGM, the triangular tooth shape is more favorable than the square one. The triangular teeth allow for roots positioned farther apart than the square ones. This spacing allows for potential thicker interproximal bone, which may minimize crestal bone loss and subsequent papilla loss after extraction and implant placement. The square or ovoid tooth shape may therefore be at an increased risk for vertical bone loss because the osseous crest is thinner. This shape, on the contrary, provides more proximal support for the interdental gingival tissue.

Site Selection. Kois (2001) proposed five diagnostic keys for predictable single tooth peri-implant esthetics. These keys include: 1) relative tooth position, 2) perio form, 3) perio biotype, 4) tooth shape, and 5) osseous crest. Prior to tooth extraction, it is critical to evaluate its position relative to the remaining dentition because the existing tooth position will influence the presenting configuration of the gingival architecture. A tooth with root proximity has very thin bone which makes it more susceptible to resorption after extraction. On the contrary, a tooth with diastemas would possess thicker interproximal bone and subsequently be less prone to resorption after extraction. Periodontal form is divided into flat, scalloped, and pronounced scalloped. A flat gingival architecture compared to a scalloped site would have less tissue coronal to the bone interproximally than facially, therefore creating less discrepancy and less risk of interproximal papilla loss following extraction. Periodontal biotype can be divided into thick and thin. Thin gingival tissue is more susceptible to trauma and increased risk for

recession and papilla loss, whereas, thicker tissue is more resistant to trauma and bacterial insults. Tooth shape can be square, ovoid, or triangular. Osseous crest position both facially and interproximally are critical for soft tissue levels following implant placement.

Implant Placement

Incisions. A variety of flap designs have been developed over the years to prevent recession and preserve interproximal papilla. Gomez-Roman (2001) conducted a study of flap design and its influence on proximal crestal bone loss around single unit implants. This study compared 2 different flap designs: a widely mobilized flap design that included the papillae, and a limited flap design to protect the papillae. One year after crown placement, the mean interproximal bone loss was significantly lower after the use of the limited flap design compared to the widely mobilized flap procedure (0.29 mm vs. 1.12 mm). The limited flap as a result minimized the risk of papilla loss. The author concluded that a clinician should use surgical techniques that prevent esthetic complications, such as increased crown length or loss of interdental papilla, without compromising osseointegration.

Mesial-Distal Placement. The mesiodistal position of the implant determines the shape of the interproximal embrasures. A standard diameter implant (3.75 mm diameter body, 4.1 mm diameter fixture table) being placed for a single-tooth restoration between two natural teeth requires at least 6.6 mm of interproximal space. At least 1.0 mm of bone should be present on either side of the implant, and an extra 0.5 mm to compensate for the periodontal ligament of each of the adjacent teeth. If these dimensions are violated, it can result in an implant that impinges on the natural tooth's periodontal

ligament and encroachment of the interproximal papilla. Tarnow et al. (2000) investigated the horizontal bone loss around an implant and found a mean loss of 1.3 to 1.4 mm. It is because of this horizontal loss that an implant should be placed ≥ 1.5 mm from the tooth. The results showed that there was a lateral component of bone loss around implants, and 3 mm was a critical interimplant distance. The crestal bone loss for implants with a greater than 3 mm distance between them was 0.45 mm, while the implants that had a distance of 3 mm or less had crestal bone loss of 1.04 mm.

Buccolingual Position. The buccolingual position of the implant affects the biomechanics and emergence profile of the restoration. Cardaropoli et al. (2006) evaluated dimensional alterations of the peri-implant tissue of single-tooth implants in the anterior maxillary region over 1 year. A mean reduction of 0.4 mm of the facial bone thickness and 0.7 mm of the facial bone height were observed between implant placement and second stage surgery. This was accompanied by a mean apical displacement of the facial soft tissue margin of 0.6 mm. Spray et al. (2000) measured the change of facial crestal bone height between implant insertion and uncovering. They found an increase in crestal resorption when the facial thickness was decreased. Based on these findings, they proposed that 2 mm of facial bone thickness should be left after implant placement to avoid future recession. Buser et al. (2004) recommended that the implant shoulder be placed 1-2 mm lingual to the emergence of the adjacent teeth to ensure maintenance of an adequate width of buccal bone and stable mucosa over the buccal implant surface. Evans and Chen (2008) reported that implants placed with a buccal shoulder exhibited three times more recession than implants with a lingual shoulder position. Grunder et al. (2005) recommended augmenting the labial bone foundation beyond the platform by at

least 2 to 4 mm to adequately compensate for the natural bone remodeling that occurs following restoration and loading.

Apicocoronal Positioning. Herman et al. (2000) showed that the location of the implant-abutment junction would determine the amount of crestal bone resorption for 2-piece implants. As a result, placing the implant-abutment deeper will typically generate greater bone loss until biologic width is established. Herman et al. (1997) reported on 1-piece nonsubmerged implants and found that the junction between the rough body and smooth collar will determine the initial bone-to-implant contact. They recommended to level this junction with the bone in an effort to minimize further bone remodeling. Buser et al. (2004) stated that the apicocoronal positioning of the implant shoulder should follow the philosophy “as shallow as possible, as deep as necessary.” If the implant shoulder is placed too far apically the vertical dimension of the bone saucerization may lead to unnecessary bone loss on the adjacent tooth. On the contrary, if the implant is placed too far coronal, then a supragingival shoulder position may lead to a visible metal margin and a poor esthetic result. Saadoun (1997) stated that to allow for adequate prosthetic space, implants should be placed 2 to 3 mm apical to the free gingival margin at the facial aspect. This would allow the vertical bone height in the proximal area to be 2 to 3 mm coronal to the implant platform, which is the ideal position.

Platform Selection. London (2001) discusses the importance of implant platform selection and its role in tissue management and development. To achieve optimal tissue support and a cleansable emergence, the platform selected should be the widest that can be contained within the contours of the tooth and still provide a subtle flared emergence. Selecting an excessive diameter can result in compromise to the interproximal bone

height, inadequate embrasure space for the papilla as well as for cleaning, and an unnatural tooth contour. Conversely, an underdimensioned implant will provide inadequate support for soft tissue contours and difficult curette access for maintenance. In simplest terms, the author suggests that implant diameter should be selected to be similar to the diameter of the root at the same level. The esthetic impact of the implant platform selection is very important. Inappropriate selection of an implant platform can lead to unachievable esthetic goals.

Table 12

London's Optimal Implant Diameters

	Small Lateral	Lateral, Small Canine, Premolar	Canine, Central
Optimal Platform	3.4 mm	4.1 mm	5 mm
Body Diameter Options	3.25 mm	3.25 mm, 3.75 mm, 4 mm	4 mm, 5 mm

Platform Switching. According to Herman et al. (1997) one year following implant restoration, dental implants restored with prosthetic components of matching diameter have crestal bone re-modelling around the coronal part of the implant and about 1.5-2 mm of vertical bone loss. Herman et al. (2001) stated that this biological width re-establishment may occur as a result of micromovements at the implant-abutment interface (IAI). Lazzara and Porter (2006) stated that platform switching could be beneficial in maintaining peri-implant marginal bone loss both mechanically (by reducing the force transmitted to the implant-bone interface) and biologically (by creating a better seal at the implant-abutment interface and relocating the inflammatory zone inward away

from the bone). Brogini et al. (2006) proposed that this bone loss may be due to bacterial migration and colonization of the micro-gap on a screw retained abutment that induce a localized chronic inflammation. Switching platform restorations creates a smaller diameter restorative component that keeps the IAI inward and away from the outer edge of the implant. Canullo et al. (2009) evaluated 22 implants with 5.5 mm platform diameters connected with either 3.8 mm or 5.5 mm diameter abutments in immediate sites. Results showed that inter-proximal papillae and soft tissue buccal margin around matching diameter IAI had significantly higher apical migration than switching to a smaller platform abutment. Cappiello et al. (2008) evaluated the bone loss around switched implants with abutment 1 mm narrower than platform compared to no platform switch. Results showed after 12 months of loading the platform switch implants had a mean vertical bone loss of 0.95 mm while the non-platform switched had 1.67 mm. This data confirmed the role of the microgap between the implant and abutment in the remodeling of the peri-implant crestal bone. They concluded that platform switching seems to reduce peri-implant crestal bone resorption and increased the long-term predictability of implant therapy. Canullo et al. (2010) investigated radiographically the benefits of different mismatching diameter switching platform and observed that an increasing implant/abutment mismatching diameter resulted in an even better marginal bone preservation.

Provisionalization. Jemt (1999) attempted to promote interimplant papillary formation by means of placing either a provisional resin crown at the time of second stage surgery. The author showed that the use of provisional crowns were able to guide the soft tissue into the interimplant space faster than healing abutments alone.

According to Santosa (2007), it provides patients with a quick and economical restoration of aesthetics and function and acts as a diagnostic scaffold to guide soft tissue contour for enhanced aesthetics.

According to David (2008) the preparation of esthetically appealing and anatomically correct implant-supported provisional restorations facilitates fabrication of the final implant-supported crown. The provisional crown is used to mould and manipulate the soft tissue and acts as a template for the final crown. This type of restoration should be placed several weeks before the final impression is taken, allowing for the maturation of the peri-implant tissue. By varying the subgingival contour of the provisional restoration, the peri-implant gingival tissue can be manipulated. On the labial surface of the provisional, the more convex the subgingival contour, the further the gingival tissue may be moved in the apical direction. Conversely, the less convex or flatter the subgingival surface, the more the tissue may be moved in the coronal direction. The papilla may be moved incisally by making the subgingival interproximal acrylic contour more convex, which pushes the tissue toward the proximal surface of the adjacent tooth and moves it incisally. Too much pressure will restrict the vascular supply to the papillary tissue and cause necrosis. When optimal peri-implant tissue levels are achieved, take an impression for fabrication of the final restoration.

Castellon et al. (2005) discussed the modalities for immediate provisionalization of single tooth implants. The authors divided the aesthetic aspects of immediate provisionalization into implant placement, abutment selection and preparation. They concluded that the benefits of immediate provisionalization were maintenance of the interdental space, development of the gingival sulcus, minimizing delay of the final

restoration, improved patient comfort and elimination of second-stage surgery.

Restorative Success. It is well established that a harmonious integration between implant-prosthetic components and surrounding soft tissue is essential for achieving optimal esthetic results. Kan et al. (2011) reported that the esthetic success of implants is influenced by a number of factors that can be identified as extrinsic or intrinsic. Extrinsic factors (clinician-dependent) include proper three-dimensional implant positioning and angulation, as well as appropriate contouring of the abutment and provisional restoration. Intrinsic factors, on the contrary, are patient-dependent and include hard and soft tissue relationships and gingival biotype.

Buser et al. (2004) states that in the anterior maxilla, unsuccessful treatment outcomes can lead to disastrous clinical situations that can only be corrected with removal of the implant and subsequent tissue augmentation procedures. With this in mind, it is important to establish sound clinical concepts with clearly defined parameters that lead to successful esthetics in the anterior maxilla, with long-term stability of the peri-implant tissues. To successfully meet the challenges of esthetic implant dentistry, a team approach is advantageous and highly recommended. The team includes an implant surgeon, a restorative clinician, and a dental technician who preferably has advanced knowledge and clinical experience. According to Belser et al. (2003) the main esthetic objectives of implant therapy from a surgical point of view are the achievement of a harmonious gingival margin without abrupt changes in tissue height, maintaining intact papillae, and obtaining or preserving a convex contour of the alveolar crest. An optimal esthetic implant restoration depends on 4 anatomic and surgical parameters: (1) submucosal positioning of the implant shoulder, (2) adequate 3-dimensional implant

positioning, (3) long-term stability of esthetic and peri-implant soft tissue contours, and (4) symmetry of clinical crown volumes between the implant site and contralateral teeth.

Soft Tissue Augmentation. Vertical loss of buccal peri-implant tissue volume may lead to recession, to a crown length differing from a contralateral tooth and to a visible abutment or implant shoulder. Missing soft tissue volume interproximally can lead to black triangles and food impaction. Therefore, a sufficient amount of tissue is of great interest regarding the esthetic outcome.

Connective Tissue Graft. Cornelini et al. (2008) conducted a study to evaluate connective tissue grafts in immediate implants with immediate restoration. 17 patients received a connective tissue graft (test group) and 17 patients received no graft (control group). Results showed a mean facial gingival gain of +0.2 mm (test group) vs. -0.85 mm (control group) 1 year after immediate implant placement and provisionalization within 24 hours.

Kan et al. (2009) reported that enhancement of gingival thickness through connective tissue augmentation at time of implant placement made gingival tissues more resistant to recession. At the mean follow-up of 2.15 years all patients exhibited a thick biotype. The mean overall facial gingival level change was a mean +0.13 mm. Thick tissue showed a gain of +0.23 mm while thin tissue showed a gain of +0.06 mm.

Chung et al. (2011) reported a case series involving immediate single tooth replacement with subepithelial connective tissue graft using platform switching implants. Results at 1-year follow-up revealed a mean facial gingival level change of -0.05 mm and more than 50% papilla fill was observed in 89% of the sites.

Wiesner et al. (2010) evaluated whether connective tissue grafts performed at

implant placement could be effective in making peri-implant soft tissues thicker. Ten patients received connective tissue grafts (test group), while 10 patients received no graft (control group). One year results after loading revealed a mean tissue thickness of 3.2 mm (test group) vs. 1.9 mm (control group). Soft tissues at grafted sites were 1.3 mm thicker ($P < 0.001$) and had a significantly better pink esthetic score ($P < 0.001$).

Tsuda et al. (2011) evaluated peri-implant tissue response following connective tissue and bone grafting in conjunction with immediate single-tooth replacement in the esthetic zone. 1-year results revealed a mean facial gingival level change of -0.05 mm and more than 50% papilla fill was observed in 80% of the sites.

Schneider et al. (2010) evaluated volume gain and stability of peri-implant tissue following bone and soft tissue augmentation in 15 patients. Augmentation included deproteinized bovine bone mineral (Bio-Oss) followed by a subepithelial connective tissue graft harvested from the palate. 1-year following crown insertion the mean change in facial gingival level was -0.22 mm and mean change in papilla level was +0.07 mm.

Alloderm. Allen (2011) reported on minimally invasive surgery for soft tissue problems at implant sites. The author states that minimally invasive grafting surgery for implants is most successful when applied to incipient problems. More invasive, conventional surgical approaches have a risk of making a minor problem worse. This report presents several cases of facial recession involving implants where either connective tissue or alloderm is placed into a pouch and coronally advanced and sutured.

Park (2011) evaluated immediate implantation with ridge augmentation using acellular dermal matrix (ADM) and deproteinized bovine bone in a case report. ADM was used as a barrier for bone augmentation to treat the implant dehiscence defect. Park

(2008) stated that the addition of ADM compared with bone graft alone enhanced the gain in thickness of bone. Park (2010) evaluated healing of an extraction socket grafted with deproteinized bovine bone and ADM in a case report. Results showed that ADM functioned well as a membrane in conjunction with a bone xenograft in ridge augmentation prior to implant placement. The underlying bone showed good healing maturity with high percentage of new bone formation.

Yan et al. (2006) compared acellular dermal matrix (ADM) and free gingival graft (FGG) in the reconstruction of keratinized tissue. A patient with inadequate keratinized tissue around dental implants in the maxillary and mandibular anterior regions received either an ADM graft or FGG. The width of keratinized tissue was recorded initially and 6 months after surgery. The gain of keratinized tissue was 7.8 mm for FGG and 2.4 mm for ADM. The net gain was 7.3 mm for FGG and 1.8 mm for ADM. The shrinkage rate was 32.4% for FGG and 82% for ADM.

CHAPTER II

METHODS

Study Design. Twenty-four patients were invited to participate in this randomized, controlled, blinded clinical trial. By random selection, using a coin toss, twelve positive control patients were selected to receive a delayed placement laser-grooved implant collar (Laser-Lok, Birmingham, Alabama) with a simultaneous connective tissue graft. Twelve test patients were selected to receive a delayed placement laser-grooved implant collar (Laser-Lok, BioHorizons, Birmingham, Alabama) with a simultaneous acellular dermal matrix allograft. The laser-grooved surface is 1.8 mm in length and consists of 8 micron grooved channels that promote connective tissue attachment, prevent apical migration of epithelium, and promote bone attachment. The surface of the implant body was a roughened RBT surface. All implants were placed in the maxillary esthetic zone, from second premolar to second premolar. A fixture level impression taken at the time of implant placement was sent to the dental laboratory for fabrication of a composite provisional restoration. Each patient received a post-surgical regimen of 50 mg doxycycline hyclate qd for 2 weeks, 375 mg naproxen one tab q 12h, and Vicodin ES one tablet q4-6h prn pain.

At two months post-surgery, implants were uncovered and a temporary abutment and provisional restoration were placed. Approximately 2 months were utilized for tissue

shaping and development of an esthetic emergence profile.

Around four months post-surgery, another fixture level impression was taken and sent to the laboratory for fabrication of a final crown restoration. The final crown examination was completed at approximately 6 months.

Primary outcome variables were implant interproximal bone loss, soft tissue thickness, and objective soft tissue esthetics evaluated using the Jemt Papilla Index (1997), the Pink Esthetic Score of (Furhauser et al., 2005), papilla harmony and gingival recession. Objective tooth esthetics were evaluated using the White Esthetic Score (Belser et al., 2009). A subjective esthetic evaluation was performed by each patient using a Visual Analog Scale for the soft tissue, the tooth, and an overall esthetic appearance.

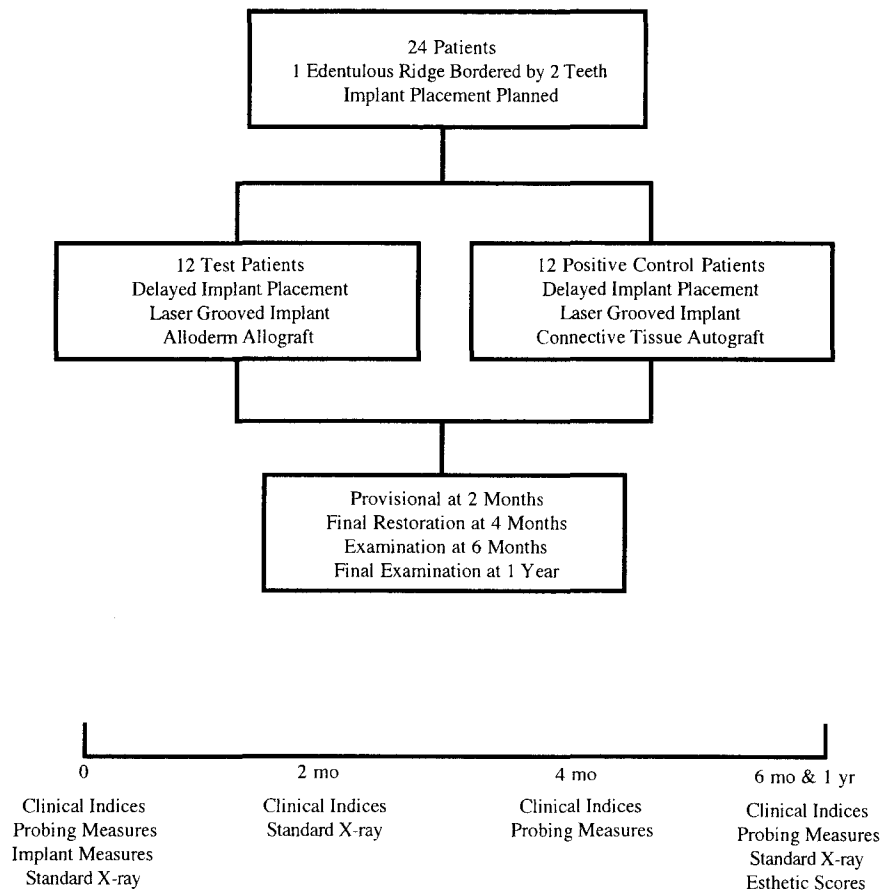


Fig. 1. Study Design.

Inclusion criteria. Inclusion criteria were: 1) Patients with one or more missing teeth in the esthetic zone of the maxilla between #4 and #13 to be replaced by dental

implants; 2) Each implant site should be bordered by two teeth; 3) Patients must be 18 years of age or greater; and 4) Informed consent must approved by University of Louisville Human Studies Committee.

Exclusion criteria. Exclusion criteria were: 1) Patients with uncontrolled diabetes, immune disease, or systemic disease that significantly affects the periodontium; 2) Previous head and neck radiation; 3) Patients who have been on IV bisphosphonates or oral bisphosphonates for > 3 years; 4) Smoker > ½ pack per day; 5) Patients who need prophylactic antibiotics prior to dental procedures; 6) Patients with allergy to any medication or material used in the study; 7) Chemotherapy in the previous 12 months; 8) Severe psychological problems; 9) Patients unable to sign the informed consent; 10) Pregnant subjects will be excluded due to risk of miscarriage; and 11) History of allergy to common dentifrice ingredients.

Post-surgical exclusion. Any patients excluded after surgery will be reported and accounted for. Post surgical exclusion criteria are as follows: 1) Implant failure; and 2) Unanticipated healing complications that will adversely affect treatment results.

Pre-surgical management. Each patient received a diagnostic work-up including standardized radiographs (periapicals [Appendix D]), study casts, clinical photographs, and a clinical examination of teeth adjacent to the edentulous sites. Pre-surgical preparation included detailed oral hygiene instructions. Baseline data was collected at initial exam.

Clinical Indices at the tooth/implant site. At baseline, indices were completed for teeth adjacent to the edentulous site. At 2, 4, 6, and 12 months the indices were completed at the implant site. Indices evaluated were: 1) Plaque index (Appendix A); 2)

Gingival index (Appendix B); 3) Mobility (Appendix C); 4) Probing depth. Measured from gingival margin to apical penetration of the probe tip; 5) Keratinized tissue: Measured from the gingival margin to the mucogingival junction; 6) Bleeding on probing (BOP): Present or absent; 7) Radiographic examination: Stents were constructed using Regisil® PB™ Plaster Bite Registration Paste and a Rinn-XCP on the patient model so that standardized radiographs could be taken at selected time intervals (Appendix D); and 8) Clinical photographs were taken at 1, 2, 4, 6, and 8-week post-op. If needed, an additional post-op picture was taken every two weeks until soft tissue closure was complete. Clinical photographs were then taken at the 4 and 6 month post-op and at the 12 month final.

Pre-surgical measurements at the tooth/implant site. Pre-surgical measurements included: 1) CEJ to osseous crest measured on the radiograph at baseline, 2, 4, and 6 months; 2) Periodontal form: Flat, scalloped, or pronounced scallop (Appendix E); 3) Periodontal biotype: Thick, moderate, or thin (Appendix F); 4) Tooth shape: Square, ovoid, or triangular; 5) Gingival scallop measured from the facial gingival margin to papillae tip; 6) Papilla harmony (Appendix G); and 7) Gingival margin harmony (Appendix H). 8) Gingival thickness

Surgical treatment. All pre-surgical measurements were taken and a preoperative radiograph was taken with a stent in place to document pre-surgical bone levels. Patients were then anesthetized with 2% xylocaine containing epinephrine in both 1:100,000 and 1:50,000 concentrations. Papilla preservation incisions were used with the ridge incision placed towards the palate. A full thickness mucoperiosteal flap was elevated on the buccal and palatal to expose the alveolar ridge. Measurements from

osseous crest to adjacent CEJ and osseous scallop were taken with a periodontal probe(s). Either a connective tissue autograft or an acellular dermal matrix allograft was randomly selected, using a coin toss, for placement at the implant site. Both control and test sites received a Biohorizons Tapered Internal Implant RBT, Laser-Lok implants. Implants were centered mesio-distally between the adjacent teeth, aligned between the incisal edge and the cingulum for canines and incisors, or with the central groove for premolars. After implant placement post-implant measurements were completed.

A fixture level impression was taken at the time of implant placement using a closed or open tray impression coping with heavy body impression material (Aquasil Ultra Heavy, Smart Wetting[®] Impression Material, Dentsply Caulk, Milford, DE) and light body impression material (Aquasil Ultra XLV Smart Wetting[®] Impression Material, Dentsply Caulk, Milford, DE). The impression was sent to ADL (Louisville, KY) where provisional crowns were fabricated. Flaps were replaced and sutured for primary closure with 4-0 silk sutures. A radiograph was taken with the stent in place to following implant placement. Patients were given naproxen 375 mg (Geneva Pharmaceuticals, Inc. Broomfield, CO), one tab q12h, doxycycline hyclate 50 mg (Warner Chilcott Inc. Morris Plains, New Jersey), 1 tab qd, and Vicodin ES[®] (Abbot Laboratories. North Chicago, Illinois) 1 tab q4-6h prn pain.

Surgical measurements. Implant site measurements included: 1) Osseous crest to adjacent CEJ measured with a periodontal probe at the mesial and distal of the implant site; 2) Osseous scallop: The vertical distance from the midfacial osseous crest to a periodontal probe positioned horizontally at the most coronal portion of the interproximal osseous crests; 3) Implant platform vertical distance from the facial osseous margin, and

the mesial and distal osseous margins; 4) Horizontal osseous crest thickness from the facial crest to the implant platform; 5) Subjective evaluation of implant placement in three dimensions (Appendix I); 6) Bone quality at implant placement (Appendix J); and 7) Clinical photographs.

Prosthetic treatment. The implants were uncovered at two months. Minimal incisions were utilized to expose the implant, and were located palatally and the tissue was pushed facially. Temporary abutments were placed on the implant and torqued to 30 Ncm. A composite (Radica[®], Dentsply Prosthetics, York, PA) provisional fabricated by the laboratory (ADL, Louisville, KY) was placed. Radica[®] was used to fabricate provisional crowns and bridges and Integrity[®] was used to modify the crown contours. Integrity[®] (Dentsply Prosthetics, York, PA) is a chemically polymerized composite resin. A radiograph was taken with stent in place to evaluate hard tissue levels.

Every two weeks for 8 weeks, patients were seen to adjust the provisional to shape the gingival contours. The contours of the provisional influence the position of the soft tissue. Removing some of the convexity from the facial of the provisional allows the tissue to migrate coronally. Increasing the facial convexity of the provisional will drive the tissue apically. Adding material to the interproximal of the provisional adds support for the papillae. After all parameters were fulfilled, including patient satisfaction, a final impression was taken, and the lab fabricated a definitive restoration.

After the soft tissue margins were established, at approximately 4 months, a final impression was taken. The provisional abutment and crown were removed and attached to an implant analog. An impression was taken of the provisional and analog using Regisil[®] (Dentsply Caulk, Milford, DE) in a small plastic cup. The provisional and the

temporary abutment were removed from the Regisil[®] impression, and an impression coping was attached to the analog, which remained in the impression. DuraLay[®] (Reliance, Worth, IL) acrylic was placed around the impression coping using a “salt and pepper” technique into the impression. The impression coping with attached DuraLay[®] was removed from the Regisil[®] impression and transferred to the implant in the mouth. The DuraLay[®] replicated the subgingival contour of the provisional, and therefore indirectly captured the subgingival emergence profile. An impression was taken using heavy body impression material (Aquasil Ultra Heavy, Smart Wetting[®] Impression Material, Dentsply Caulk, Milford, DE) and light body impression material. A shade was chosen by the patient using a Portrait IPN[®] shade guide (Dentsply Trubyte, York, PA) and sent to ADL along with the final impression and a photo of the area. Another radiograph was taken with stent in place to evaluate hard tissue levels.

When the final restoration returned from the lab, the patient was appointed and the crown was placed. The provisional and the temporary abutment were removed. The final abutment was placed and torqued to 30 Ncm. Occlusion and contacts were checked, and the final restoration was cemented into place with permanent cement FUJI II[®].

Patients were then scheduled for the 6-month exam, which was at least 2 weeks after the restoration, was placed. A radiograph was taken with the stent in place to evaluate hard tissue parameters. Clinical photographs and the collection of final data including the Jemt papilla index (Appendix M), the Pink Esthetic Score index (Appendix K), and the White Esthetic Score (Appendix L) were taken. Patients completed three questions on a Visual Analog Scale to assess patient subjective evaluation of esthetics (Appendix N).

Radiographic and clinical measurements for the implant at 2, 4, 6, and 12 months were taken. Radiographic and clinical measurements for implant included: 1) Location of interproximal contact mesial and distal: Ideal, incisal or apical; 2) Vertical length of interproximal contact mesial and distal: Short, normal, or long; 3) Osseous crest to contact; 4) Osseous crest to contact radiographic (6 month only); 5) Osseous crest to CEJ; 6) Osseous crest to CEJ radiographic; 7) Facial recession; 8) Emergence (implant top to gingival margin) facial, mesial, distal; 9) Gingival scallop; 10) Papilla harmony (Appendix G); 11) Gingival margin harmony (Appendix H); and 12) Black triangle.

Restoration Form. Restoration form included: 1) Contact location: Ideal, incisal, or apical; 2) Contact length: Normal, long, or short; 3) Restorative margin: Good, overhung, or overextended; and 4) Emergence profile: Good, overbulked, or undercontoured.

Measurement techniques. All probing measurements were taken using the University of North Carolina probe. A masked, calibrated examiner (Appendix N) performed the initial examination and all study measurements. Standardized periapical radiographs and measurements were taken at the 2, 4, and 6-month examinations.

Statistical Analysis. Means and standard deviations were calculated for all parameters. A paired t-test was used to evaluate the statistical significance of the differences between initial and final data. An unpaired t-test was used to evaluate statistical differences between the test and control groups. A sample size of 12 gave at least 80% statistical power to detect a difference of 0.4 mm soft tissue thickness both within and between groups.

CHAPTER III

RESULTS

A total of 6 females and 5 males with a mean age of 59, ranging from 32 to 77, were enrolled. The connective tissue (CT) group consisted of 4 maxillary central incisors and 2 maxillary premolars. The acellular dermal matrix (ADM) group consisted of 2 maxillary canines and 3 maxillary premolars. There were no smokers enrolled in either the CT or ADM group. Subjective assessment at the time of implant placement indicated that for the ADM group 4 implants were placed in Type 2 bone and 1 was placed in Type 3 bone; for the CT group 4 implants were placed in Type 2 bone and 2 were placed in Type 3 bone. Data from this study was derived from 11 patients completed by Dr. Thomas Peterson.

Implant Positioning

Implant Placement Data. At placement, the mean vertical distance from the implant platform to the osseous crest for CT cases was 0.2 ± 0.4 mm on the mid-facial, -2.6 ± 1.1 mm on the mesial, and -2.6 ± 1.0 mm on the distal (a negative sign indicates that the bone crest was coronal to the implant platform, Table 13). For ADM cases, the mean distance was 0.5 ± 0.8 mm on the mid-facial, -3.5 ± 0.4 mm on the mesial, and -3.2 ± 0.5 mm on the distal. There were no statistically significant differences between groups for any of these vertical distances ($p > 0.05$, Table 13). The mean horizontal distance from the implant collar to the facial osseous crest was 1.2 ± 0.7 mm for CT cases

and 1.2 ± 0.4 mm for ADM cases ($p > 0.05$, Table 13). The mean horizontal interproximal distance from tooth to implant for CT cases was 2.9 ± 0.3 mm on the mesial and 2.7 ± 0.4 mm on the distal (Table 13). For ADM, the distance was 2.9 ± 0.5 mm on the mesial and 3.2 ± 0.3 mm on the distal (Table 13). There were no statistically significant differences between groups for any of these horizontal measurements ($p > 0.05$, Table 13). The mean osseous scallop existing or created at the time of implant placement was 3.2 ± 0.7 mm for the CT sites and 2.5 ± 0.5 mm for the ADM sites ($p > 0.05$).

Emergence Profile Data

Implant Platform to Gingival Margin. The mean distance from the implant platform to gingival margin at 6 months for the CT group was 3.3 ± 0.5 mm on the facial, 5.1 ± 1.0 mm on the mesial, and 5.0 ± 0.7 mm on the distal. The mean distance from the implant platform to gingival margin at 6 months for the ADM group was 3.5 ± 1.1 mm on the facial, 5.1 ± 1.0 mm on the mesial, and 5.1 ± 1.1 mm on the distal. There were no statistically significant differences between groups for any of these vertical measurements ($p > 0.05$, Table 14).

Critical Dimensions Related to Papilla Formation

Osseous Crest to Contact Distance. At 6 months, the mean distance from adjacent tooth osseous crest to the contact for CT sites was 4.7 ± 1.0 mm and 3.9 ± 1.0 on the mesial and distal, respectively, and 4.8 ± 0.8 and 3.9 ± 1.7 for the ADM sites on the mesial and distal, respectively (Table 15). There were no statistically significant differences between groups for either mesial or distal measures ($p > 0.05$).

Implant to Tooth Distance. Mean implant to tooth distance for the CT group was 2.9 ± 0.3 mm on the mesial and 2.7 ± 0.4 mm on the distal (Table 15). Mean implant

to tooth distance for the ADM was 2.9 ± 0.5 for the mesial and 3.2 ± 0.3 for the distal. There were no statistically significant differences between groups for either mesial or distal measures ($p > 0.05$, Table 15).

Soft Tissue Thickness

Thickness at the Crest and 5 mm apical. The CT thickness at the crest was 2.6 ± 0.7 at time 0 and increased to 3.1 ± 0.7 mm at 4 months for a mean change of 0.5 ± 0.6 mm ($p > 0.05$, Table 16). The ADM thickness at the crest was 2.3 ± 0.7 at time 0 which increased to 3.1 ± 1.3 mm at 4 months for a mean change of 0.8 ± 1.6 mm ($p > 0.05$). The CT thickness 5 mm apical to crest was 2.6 ± 1.6 at time 0 and increased to 2.7 ± 0.6 at 4 months for a mean change of 0.1 ± 1.5 mm. The ADM thickness 5 mm apical to crest was 2.0 ± 0.8 at time 0 and increased to 2.6 ± 0.7 at 4 months for a mean change of 0.6 ± 1.1 mm. There were no statistically significant differences between groups at any time ($p > 0.05$, Table 16).

Measures of Recession and Papilla Fill

Gingival Margin Harmony and Recession Data. The CT sites presented with a mean of 0.5 ± 0.5 mm recession at the 4-month measurement with no change at 6 months ($p > 0.05$, Table 14). ADM cases presented with a mean of 1.0 ± 1.0 mm recession at 4 months which decreased to 0.6 ± 0.5 mm at 6 months for a mean change of -0.4 ± 0.5 mm ($p > 0.05$). There were no statistically significant differences between CT and ADM groups ($p > 0.05$, Table 14). Gingival margin harmony was achieved in 40% (2 of 5) of CT cases at 6 months and 50% (3 of 6) of the ADM cases at 6 months (Table 17).

Black Triangle, Papilla Harmony, and Gingival Scallop Data. The mean black triangle size for the CT sites decreased on the mesial from 4 to 6 months from $2.8 \pm$

1.8 mm to 1.3 ± 1.4 mm, for a mean change of -1.5 ± 0.8 mm ($p < 0.05$), and on the distal from 2.5 ± 0.8 mm to 1.4 ± 1.1 mm for a mean change of -1.1 ± 0.6 ($p < 0.05$, Table 14). Both mesial and distal mean papilla changes in CT group were statistically significant. The mean black triangle size for the ADM sites also decreased on the mesial from 4 to 6 months from 2.4 ± 0.8 mm to 1.6 ± 1.1 mm, for a mean change of 0.8 ± 0.5 mm ($p < 0.05$), and on the distal from 2.7 ± 0.7 mm to 2.1 ± 1.0 mm for a mean change of 0.6 ± 0.6 ($p > 0.05$). The mesial mean papilla change for ADM was statistically significant ($p < 0.05$). Papilla harmony was achieved in 50% (3 of 6) of cases in the CT group and 20% (1 of 5) of cases in the ADM group (Table 17). The mean gingival scallop for the CT sites was 1.5 ± 0.9 mm at 2 months and increased to 2.7 ± 0.7 at 6 months for a gain of 1.2 ± 0.8 mm ($p < 0.05$). The mean gingival scallop for the ADM sites was 1.0 ± 0.9 mm at 2 months and increased to 2.1 ± 1.0 at 6 months for a gain of 1.2 ± 0.7 mm ($p < 0.05$). There were no statistically significant differences between groups ($p > 0.05$).

Subjective and Objective Esthetic Assessments

Objective Evaluation of Esthetic Success. The mean pink esthetic score (Furhauser et al. 2005) for the CT group was 11.8 ± 1.3 , and 10.9 ± 0.9 for the ADM group ($p > 0.05$, Table 18). The Jemt papilla index (Jemt 1997) on the mesial was 2.1 ± 0.8 for the CT group and 2.0 ± 0.0 for the ADM group ($p > 0.05$, Table 18). The Jemt papilla index on the distal was 1.8 ± 0.7 for the CT group and 1.5 ± 0.5 for the ADM group ($p > 0.05$). Using the Jemt index, CT cases had $\geq 50\%$ papilla present in 83% (10 of 12) of cases versus 80% (8 of 10) for ADM cases (Table 18). The mean white esthetic score (Belser et al. 2009) for the CT group was 7.3 ± 1.3 , and 8.0 ± 2.0 for the ADM group (Table 18).

Patient Subjective Evaluation of Implant Esthetics. Patients were asked to evaluate tooth esthetics, gingival esthetics, and overall esthetics on a visual analog scale that measured 100 mm in length. Results for tooth esthetics was a mean score of 98.2 ± 2.0 for CT cases and 97.2 ± 2.6 for ADM cases ($p > 0.05$, Table 18). Gingival esthetics was a mean score of 94.3 ± 5.6 for CT cases and 96.8 ± 3.1 for ADM cases ($p > 0.05$). Overall esthetics was a mean score of 98.5 ± 1.8 for CT cases and 97.4 ± 2.5 for ADM cases ($p > 0.05$).

Indicators of Peri-implant Tissue Health

Clinical Indices. In both groups the plaque index, gingival index and bleeding on probing index had low mean values at 4 and 6 months. Mean plaque index for the CT group was 0.4 ± 0.2 at 4 months and 6 months ($p > 0.05$, Table 20). Mean plaque index for the ADM group changed from 0.2 ± 0.2 at 4 months to 0.3 ± 0.1 at 6 months for a mean change of 0.1 ± 0.1 ($p > 0.05$). There were no statistically significant differences between groups for mean plaque index scores ($p > 0.05$, Table 20). Mean gingival index for the CT group was 0.4 ± 0.2 at 4 and 6 months ($p > 0.05$, Table 20). Mean gingival index for the ADM group was 0.2 ± 0.2 at 4 months to 0.3 ± 0.1 at 6 months for a mean change of 0.1 ± 0.1 ($p > 0.05$). There were no statistically significant differences between groups for mean gingival index scores ($p > 0.05$, Table 20). Minimal change was observed between bleeding on probing or keratinized tissue between 4 and 6 months for both CT and ADM groups (Table 20). There were no statistically significant differences from 4 to 6 month values or between groups for either of these variables ($p > 0.05$).

Probing Depth. The CT sites had a mean probing depth of 2.0 ± 0.1 at 4 months and 2.1 ± 0.2 mm at 6 months for a mean change of 0.1 ± 0.2 mm ($p > 0.05$, Table 20). The ADM sites had a mean probing depth of 2.1 ± 0.4 at 4 months which decreased to 2.0 ± 0.5 mm at 6 months for a mean change of -0.1 ± 0.2 mm ($p > 0.05$). There were no statistically significant differences between groups at any time ($p > 0.05$, Table 20).

Osseous Crest to CEJ. Between 0 and 6 months, there was ≤ 0.5 mm of mean bone loss from the adjacent tooth CEJ to the osseous crest on the mesial and distal for both groups. There was 0.3 ± 0.6 mm of mean bone gain on the mesial and 0.4 ± 0.8 mm gain for the distal in the CT group ($p > 0.05$, Table 21); and 0.5 ± 0.4 mm of mean bone loss on the mesial and 0.1 ± 0.5 mm gain for the distal in the ADM group ($p > 0.05$). There were no statistically significant differences between groups ($p > 0.05$, Table 21).

Implant Platform to Mesial and Distal Osseous Crest. Implant platform to mesial osseous crest radiographically for the CT group was a mean of 0.0 ± 0.0 at time 0 and increased to 0.5 ± 0.4 at 6 months for a mean change of 0.5 ± 0.4 ($p < 0.05$, Table 22). Implant platform to distal osseous crest radiographically for the CT group was a mean of 0.0 ± 0.0 at time 0 and increased to 0.5 ± 0.3 at time 6 for a mean change of 0.5 ± 0.3 ($p < 0.05$). Implant platform to mesial osseous crest radiographically for the ADM group was a mean of 0.0 ± 0.0 at time 0 and increased to 0.4 ± 0.5 at 6 months for a mean change of 0.4 ± 0.5 ($p > 0.05$). Implant platform to distal osseous crest radiographically for the ADM group was a mean of 0.0 ± 0.0 at time 0 and changed to 0.4 ± 0.5 at time 6 for a mean change of 0.4 ± 0.5 ($p > 0.05$). There were no statistically significant differences between groups ($p > 0.05$, Table 22). Changes are also reported from 2

months, the time of implant uncovering, until the 6-month final measurements (Table 22).

Table 13
Implant Placement Data
Mean ± sd in mm

	Facial	Mesial	Distal
<u>Acellular Dermal Matrix</u>			
Implant - Osseous Vertical	0.5 ± 0.8	-3.5 ± 0.4	-3.2 ± 0.5
Implant – Facial Bone Horiz	1.2 ± 0.4		
Implant - Tooth Mesial-Distal		2.9 ± 0.5	3.2 ± 0.3
<u>Connective Tissue</u>			
Implant - Osseous Vertical	0.2 ± 0.4	-2.6 ± 1.1	-2.6 ± 1.0
Implant – Facial Bone Horiz	1.2 ± 0.7		
Implant - Tooth Mesial-Distal		2.9 ± 0.3	2.7 ± 0.4

Table 14
Soft Tissue Dimensions
Mean ± sd in mm

	Time 4	Time 6	Change
<u>Acellular Dermal Matrix</u>			
Implant- Gingival Margin M	5.8 ± 0.5	5.1 ± 1.1	-0.7 ± 0.7
Implant- Gingival Margin D	5.3 ± 0.8	5.1 ± 1.1	-0.2 ± 0.5
Implant- Gingival Margin F	3.4 ± 1.3	3.5 ± 1.1	0.1 ± 0.5
Recession Facial	1.0 ± 1.0	0.6 ± 0.5	0.4 ± 0.5
Black Triangle Mesial	2.4 ± 0.8	1.6 ± 1.1	0.8 ± 0.5*
Black Triangle Distal	2.7 ± 0.7	2.1 ± 1.0	0.6 ± 0.6
<u>Connective Tissue</u>			
Implant- Gingival Margin M	6.0 ± 1.5	5.1 ± 1.0	-0.9 ± 1.4
Implant- Gingival Margin D	5.5 ± 1.5	5.0 ± 0.7	-0.5 ± 1.8
Implant- Gingival Margin F	3.4 ± 1.3	3.3 ± 0.5	-0.1 ± 1.0
Recession Facial	0.5 ± 0.5	0.5 ± 0.5	0.0 ± 0.1
Black Triangle Mesial	2.8 ± 1.8	1.3 ± 1.4	1.5 ± 0.8*
Black Triangle Distal	2.5 ± 0.8	1.4 ± 1.1	1.1 ± 0.6*

Table 15
Dimensions Related to Papilla Formation

Mean ± sd in mm

Time 6	
<u>Acellular Dermal Matrix</u>	
Mesial	
Osseous Crest - Contact	4.8 ± 0.8
Implant - Tooth	2.9 ± 0.5
Distal	
Osseous Crest - Contact	3.9 ± 1.7
Implant - Tooth	3.2 ± 0.3
<u>Connective Tissue</u>	
Mesial	
Osseous Crest - Contact	4.7 ± 1.0
Implant - Tooth	2.9 ± 0.3
Distal	
Osseous Crest - Contact	3.9 ± 1.0
Implant - Tooth	2.7 ± 0.4

Table 16

Tissue Thickness Dimension

Mean \pm sd in mm

	Time 0	Time 4	Change
<u>Acellular Dermal Matrix</u>			
Thickness at Crest	2.3 \pm 0.7	3.1 \pm 1.3	0.8 \pm 1.6
Thickness 5 mm apical	2.0 \pm 0.8	2.6 \pm 0.7	0.6 \pm 1.1
<u>Connective Tissue</u>			
Thickness at Crest	2.6 \pm 0.7	3.1 \pm 0.7	0.5 \pm 0.6
Thickness 5 mm apical	2.6 \pm 1.6	2.7 \pm 0.6	0.1 \pm 1.5

Table 17

Frequency of Papilla and Gingival Margin Harmony

	ADM	CT
Papilla Harmony	20% (1 of 5)	50% (3 of 6)
Gingival Margin Harmony	40% (2 of 5)	50% (3 of 6)

Table 18

Objective and Subjective Evaluation of Implant Esthetics

	ADM	CT
Pink Esthetic Score	10.9 ± 0.9	11.8 ± 1.3
White Esthetic Score	8.0 ± 2.0	7.3 ± 1.3
Jemt Papilla Index Mesial	2.0 ± 0.0	2.1 ± 0.8
Jemt Papilla Index Distal	1.5 ± 0.5	1.8 ± 0.7
Visual Analog Tooth	97.2 ± 2.6	98.2 ± 2.0
Visual Analog Gingiva	96.8 ± 3.1	94.3 ± 5.6
Visual Analog Overall	97.4 ± 2.5	98.5 ± 1.8

Table 19

Jemt Papilla Index Stratified by Amount of Vertical Papilla Height

	Jemt Score	ADM	CT
<u>Complete</u>	3 or 4	0% (0 of 10)	25% (3 of 12)
<u>≥ 50% Papilla</u>	2, 3 or 4	80% (8 of 10)	83% (10 of 12)
<u>< 50% Papilla</u>	0 or 1	20% (2 of 10)	17% (2 of 12)

Table 20
Clinical Indices
Mean ± sd in mm

	Visit 4	Visit 6	Change
<u>Acellular Dermal Matrix</u>			
Plaque Index	0.2 ± 0.2	0.3 ± 0.1	0.1 ± 0.1
Gingival Index	0.2 ± 0.2	0.3 ± 0.1	0.1 ± 0.1
Bleeding on Probing	0.0 ± 0.1	0.0 ± 0.0	0.0 ± 0.1
Keratinized Tissue	5.0 ± 0.7	5.0 ± 0.7	0.0 ± 0.0
Mean Probing Depth	2.1 ± 0.4	2.0 ± 0.5	-0.1 ± 0.2
<u>Connective Tissue</u>			
Plaque Index	0.4 ± 0.2	0.4 ± 0.2	0.0 ± 0.1
Gingival Index	0.4 ± 0.2	0.4 ± 0.2	0.0 ± 0.1
Bleeding on Probing	0.1 ± 0.1	0.1 ± 0.1	0.0 ± 0.1
Keratinized Tissue	4.7 ± 1.0	4.7 ± 1.0	0.0 ± 0.0
Mean Probing Depth	2.0 ± 0.1	2.1 ± 0.2	0.1 ± 0.2

Table 21
Adjacent Tooth Bone Loss
Mean ± sd in mm

	Time 0	Time 6	Change
Osseous Crest – CEJ			
Radiographic			
<u>Acellular Dermal Matrix</u>			
Mesial	3.1 ± 1.1	3.6 ± 1.4	-0.5 ± 0.4
Distal	3.0 ± 1.2	2.9 ± 1.5	+0.1 ± 0.5
<u>Connective Tissue</u>			
Mesial	2.6 ± 0.5	2.3 ± 0.5	+0.3 ± 0.6
Distal	2.4 ± 1.2	2.0 ± 0.7	+0.4 ± 0.8

Table 22

Radiographic Implant Platform to Interproximal Osseous Crest

Mean \pm sd in mm

	Time 0	Time 6	Change 0-6
<u>Acellular Dermal Matrix</u>			
Implant to Oss Crest M	0.0 \pm 0.0	-0.4 \pm 0.5	-0.4 \pm 0.5
Implant to Oss Crest D	0.0 \pm 0.0	-0.4 \pm 0.5	-0.4 \pm 0.5
<u>Connective Tissue</u>			
Implant to Oss Crest M	0.0 \pm 0.0	-0.5 \pm 0.4	-0.5 \pm 0.4*
Implant to Oss Crest D	0.0 \pm 0.0	-0.5 \pm 0.3	-0.5 \pm 0.3*
	Time 2	Time 6	Change 2-6
<u>Acellular Dermal Matrix</u>			
Implant to Oss Crest M	-0.3 \pm 0.4	-0.4 \pm 0.5	-0.1 \pm 0.2
Implant to Oss Crest D	-0.5 \pm 0.6	-0.4 \pm 0.5	0.1 \pm 0.2
<u>Connective Tissue</u>			
Implant to Oss Crest M	-0.3 \pm 0.8	-0.5 \pm 0.4	-0.2 \pm 1.1
Implant to Oss Crest D	-0.3 \pm 0.7	-0.5 \pm 0.3	-0.2 \pm 1.0

CHAPTER IV

DISCUSSION

The aim of this randomized, controlled, blinded clinical trial was to compare the hard and soft tissue healing around a laser-grooved implant placed with either a simultaneous connective tissue (CT) autograft or an acellular dermal matrix (ADM) allograft into a single edentulous site in the maxillary anterior esthetic zone from second premolar to second premolar. Healing was similar for both the CT and ADM grafted sites.

Implant Placement. Implant placement objectives were established mesio-distally, facially-lingually and apico-coronally. Implants were centered mesio-distally between the adjacent teeth with at least 1.5 mm between the implant body and the tooth (Tarnow et al. 2000). Facially-lingually the implant was aligned between the adjacent incisal edge and cingulum for incisors and canines, or with the central groove for premolars with at least 1 mm of bone facial to the implant body (Spray et al. 2000, Buser et al. 2004, Grunder et al. 2005). The osseous crest was scalloped in order to achieve an apico-coronal position with the implant platform even with the facial osseous crest, while keeping the platform approximately 2 to 3 mm apical to the adjacent gingival margins (Buser et al. 2004). Mean placement data indicates that these objectives were achieved (Table 13).

Implant Bone Loss. The Laser-Lok implant used in this study consists of a 1.8 mm collar with 8 μ m grooves to prevent apical migration of the epithelium and to promote both connective tissue and osseous attachment. The mean radiographic interproximal osseous position on the laser-grooved implants at 6 months was approximately 0.5 mm apical to the interproximal platform in the CT group and 0.4 mm in the ADM group (Table 22). The majority of bone loss occurred between time 0 and time 2 (provisional placement).

Tissue Thickness. Kan et al. (2011) showed that sites with thicker gingival biotypes demonstrated statistically significantly smaller changes in facial gingival levels than sites with thinner gingival biotypes at time of placement. Kan et al. (2009) evaluated soft tissue changes following immediate implant placement with simultaneous connective tissue graft and showed at a mean follow-up of 2.15 years that all patients exhibited a thick biotype. Woodyard et al. (2004) studied the effects of acellular dermal matrix plus a coronally positioned flap (CPF) on gingival thickness and root coverage compared to a CPF alone. Results showed a mean tissue thickness increase at the base of the sulcus of 0.4 mm and a gain in keratinized tissue of 0.8 mm. In the present study tissue thickness at crown placement was similar for both CT and ADM groups (Table 16). Tissue thickness at the crest was 3.1 mm for both groups, while 5 mm apical to crest revealed a thickness of 2.7 mm for CT and 2.6 mm for ADM. However, the change in tissue thickness from implant placement to crown placement was greater for sites receiving an ADM allograft. For the ADM group, the change in thickness at the crest was 0.8 ± 1.6 mm, while the CT group had a change of 0.5 ± 0.6 mm. 5 mm apical to the crest, the ADM group exhibited a change of 0.6 ± 1.1 mm, while the CT thickness

increased by only 0.1 ± 1.5 mm. Although these differences were not statistically significant, the greater change noted in the ADM group may be clinically significant (Table 16).

Recession. At 6 months the mean recession relative to the adjacent gingival margins was 0.5 mm for the CT group and 0.6 mm for the ADM group (Table 14). This is in accordance with numerous studies previously published, which show up to 1 mm loss during the first year. One factor in preventing recession is achieving proper implant placement with approximately 2 mm of facial bone thickness (Buser et al. 2004, Grunder et al. 2005). Mean facial bone thickness actually achieved in this study was 1.2 mm for both the CT and ADM groups. Tissue biotype can also affect facial recession. In this study biotype was subjectively rated as thick, moderate or thin (Kan 2003, Zigdon & Machtei 2008). The CT group had 2 thin and 4 moderate sites while the ADM group had 4 moderate sites and 1 thick site. Another factor that may influence facial recession is the width of the keratinized tissue (Kim 2009, Zigdon & Machtei 2008). In this study at 6 months the CT sites had a mean of 4.7 mm of keratinized tissue and the ADM had 5.0 mm. Thus the facial bone thickness, the tissue biotype and the width of the keratinized tissue were similar for both treatment groups, which may have contributed to the similar amount of recession for both groups.

Facial recession was assessed relative to the gingival margins on adjacent teeth in this study. This method has been utilized in previous studies (Kan et al. 2003). Thus gingival margin harmony, or appropriate margin position relative to the adjacent teeth was achieved 50% of the time for the CT group and 40% of the time for the ADM group (Table 17). The soft tissue margin may also be assessed relative to the incisal edge,

which provides a better assessment of marginal stability and change rather than actual recession (Gotfredsen 2004, Cooper et al. 2007). Since the implant does not have a CEJ "true" recession is not an objective, direct measurement. The best measure may be relative to adjacent gingival margins. Even this assessment can be compromised when adjacent margins are themselves in a receded position. In this case gingival margin harmony is the best indicator of the appropriate gingival margin position.

Papilla Formation. The presence of a papilla that completely fills a natural, normally sized interproximal space apical to a properly sized and located contact area is an important esthetic outcome. Papilla fill, however, can be achieved by decreasing the vertical height of the embrasure through the use of a long contact area. Thus papilla esthetics are best assessed using the dual measures of papilla fill and papilla harmony. The papilla height should be harmonious with the papillae on adjacent teeth. In this study papilla fill was assessed by measuring the "black triangle" or the space between the papilla tip and the base of the contact, the Jemt score (Jemt 1997), and by evaluating papilla harmony. The CT group had a Jemt score of 2.1 ± 0.8 mm on the mesial and 1.8 ± 0.7 mm on the distal, while the ADM group had a Jemt score of 2.0 ± 0.0 mm on the mesial and 1.5 ± 0.5 mm on the distal ($p > 0.05$, Table 18). The mean black triangle size for the CT sites decreased on the mesial from 4 to 6 months from 2.8 ± 1.8 mm to 1.3 ± 1.4 mm, for a mean change of -1.5 ± 0.8 mm ($p < 0.05$), and on the distal from 2.5 ± 0.8 mm to 1.4 ± 1.1 mm for a mean change of -1.1 ± 0.6 ($p < 0.05$, Table 14). Both mesial and distal mean papilla changes in CT group were statistically significant. The mean black triangle size for the ADM sites also decreased on the mesial from 4 to 6 months from 2.4 ± 0.8 mm to 1.6 ± 1.1 mm, for a mean change of 0.8 ± 0.5 mm ($p < 0.05$), and

on the distal from 2.7 ± 0.7 mm to 2.1 ± 1.0 mm for a mean change of 0.6 ± 0.6 ($p > 0.05$). The mesial mean papilla change for ADM was statistically significant ($p < 0.05$).

Another indicator of the potential for papilla fill is the interproximal bone level on the tooth adjacent to the implant. Thus the CEJ to osseous crest distance can be objectively measured. Previous studies have established that an osseous crest to contact distance of about 5 mm is a good predictor that papilla fill will be achieved between an implant and a tooth (Grunder 2000, Choquet et al. 2001, Kan et al. 2003, Gastaldo et al. 2004). This vertical distance is not the only variable affecting the papilla, which is a three dimensional structure, and the horizontal distance from implant to tooth must also be considered. Previous studies have shown that a horizontal distance of about 3 mm favors the best papilla result while greater or lesser distances may compromise papilla formation (Gastaldo 2004, Lops et al. 2008, Romeo et al. 2008, Tarnow et al. 2000, Buser et al. 2004, Grunder et al. 2005). In this study the mean osseous crest to CEJ distance on adjacent teeth was between 2 and 2.3 mm for the CT group and between 2.9 and 3.6 mm for the ADM group at time 6 (Table 21). A distance of 1 to 2 mm would have been preferred since that would indicate no interproximal bone loss.

The osseous crest to contact distance (Table 15) for both the CT and ADM groups ranged between 3.9 and 4.8 mm and was thus less than the 5.0 mm specified by Choquet et al. (2001) as necessary to gain complete papilla fill. The horizontal distance from tooth to implant was approximately 3 mm for both groups (Table 15). The combination of these vertical and horizontal distance produced black triangles ranging between 1.3 and 1.4 mm for CT sites and 1.6 to 2.1 mm at time 6. This corresponded with papilla harmony of 50% at CT sites and 20% at ADM sites (Table 17). Previous studies have

shown improved papilla fill at 1 or more years after crown insertion (Jemt 1997, Schropp et al. 2008, Cardaropoli et al. 2006). In this study $\geq 50\%$ papilla fill was achieved in 83% of the CT sites compared to 80% in the ADM sites. These numbers correspond well with previous reports of papilla fill at the time of crown insertion (Degidi et al. 2008a, Jemt 1999).

The Pink Esthetic Score (PES), an objective index of soft tissue esthetics evaluating papilla, gingival margin, soft tissue contour, color, and texture, by a dental professional, with a score of 0 (worst) and 14 (best), and each of seven categories receiving a score of 0, 1 or 2 (Furhauser et al. 2005). In this study, the results of the PES were 11.8 ± 1.3 for the CT group and 10.9 ± 0.9 for the ADM group (Table 18). The White Esthetic Score (WES), an objective index of hard tissue esthetics evaluates tooth form, volume, color, texture, and translucency, by a dental professional, with a score of 0 (worst) and 10 (best), with each of the five categories receiving a score of 0, 1, or 2 (Belser et al. 2009). In this present study, the results of the WES were 7.3 ± 1.3 for the CT group and 8.0 ± 2.0 for the ADM group (Table 18). A visual analog scale was also used in this study as a subjective assessment, to determine patient satisfaction with the tooth alone, the gingiva alone and the overall tooth plus gingival appearance. Both, groups received high scores for all categories. Visual analog tooth was 98.2 ± 2.0 for the CT group and 97.2 ± 2.6 for the ADM group (Table 18). Visual analog gingival was 94.3 ± 5.6 for the CT group and 96.8 ± 3.1 for the ADM group. Visual analog for overall appearance was 98.5 ± 1.8 for the CT group and 97.4 ± 2.5 for the ADM group (Table 18).

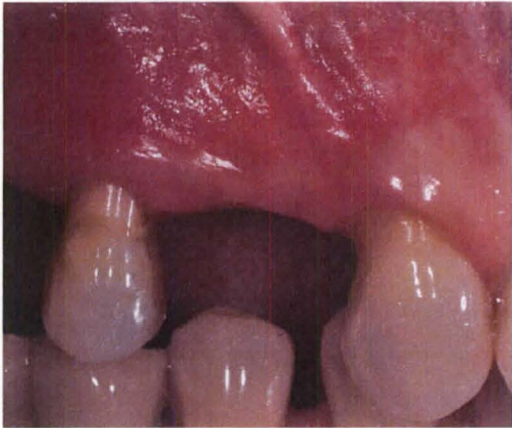CHAPTER V

CONCLUSIONS

Within the limitations of this study design the following conclusions were reached:

- 1) Both the acellular dermal matrix and the connective tissue groups had an increase in soft tissue thickness of at least 0.5 mm.
- 2) Objective and subjective esthetic scores were similar for acellular dermal matrix and connective tissue groups.
- 3) Bone loss after provisional placement was minimal and less than 0.2 mm for both groups.

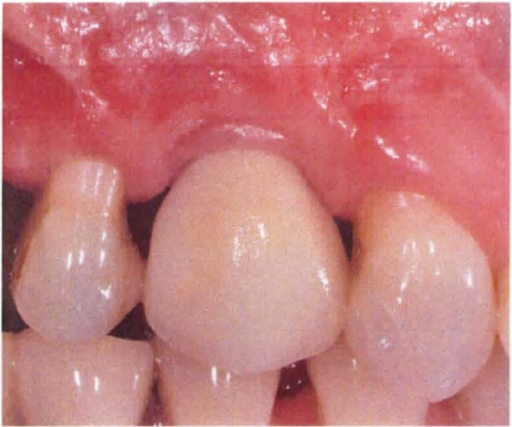
Figure 2. a) ADM Buccal Pre-op;



b) ADM Occlusal Pre-op

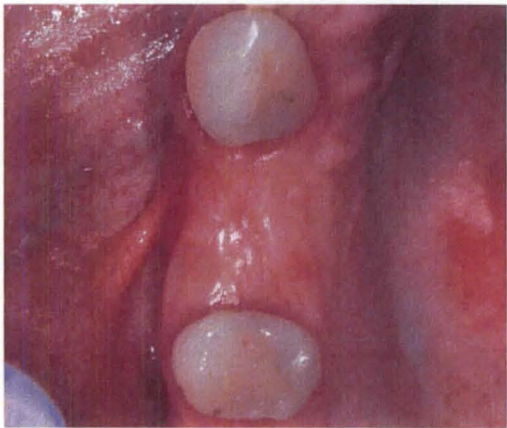

Figure 2. c) ADM Buccal Post-op;



d) ADM Occlusal Post-op

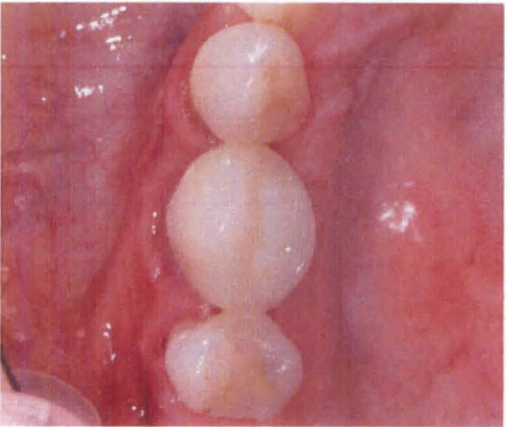
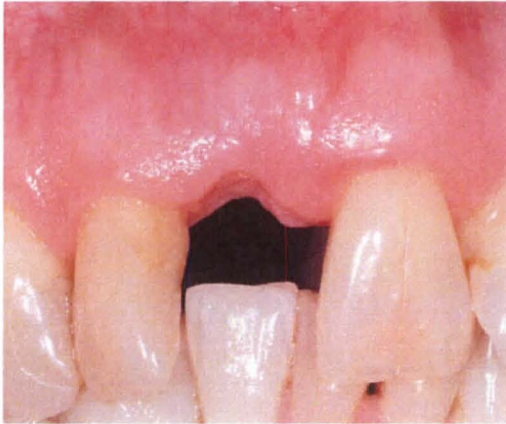


Figure 3. a) CT Buccal Pre-op;



b) CT Occlusal Pre-op

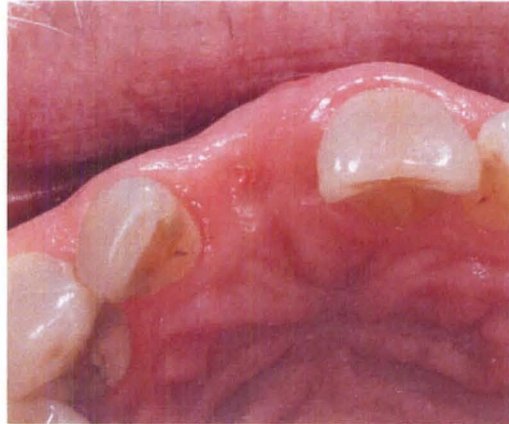
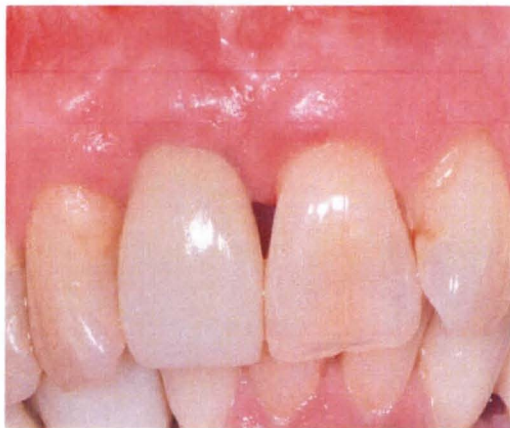
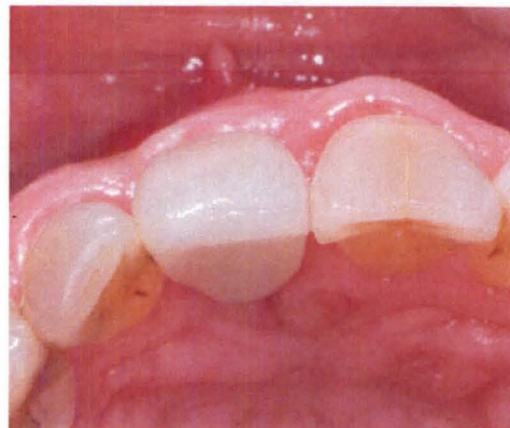Figure 3. c) CT Buccal Post-op;



d) CT Occlusal Post-op



REFERENCES

- Aalam A, Nowzari H. Clinical evaluation of dental implants with surfaces roughened by anodic oxidation, dual acid-etched implants, and machined implants. *Int J Oral Maxillofac Implants* 2005;20:793-798.
- Albrektsson T, Zarb G, Worthington P, Eriksson AR. The long term efficacy of currently used dental implants: A review and proposed criteria of success. *Int J Oral Maxillofac Implants* 1986;1(1):11-25.
- Andersson B, Odman P, Lindvall A, Lithner B. Single-tooth restorations supported by osseointegrated implants: results and experiences from a prospective study after 2 to 3 years. *Int J Oral Maxillofac Implants* 1995;10:702-711.
- Andersson B, Odman P, Widmark G, Waas A. Anterior tooth replacement with implants in patients with a narrow alveolar ridge form. A clinical study using guided tissue regeneration. *Clin Oral Implants Res* 1993;4(2):90-98.
- Avivi-Arber L, Zarb GA. Clinical effectiveness of implant-supported single-tooth replacement: the Toronto study. *Int J Oral Maxillofac Implants* 1996;11:311-321.
- Becker W, Ochsenein C, Tibbetts L, Becker BE. Alveolar bone anatomic profiles as measured from dry skulls. Clinical ramifications. *J Clin Periodontol* 1997;24(10):727-731.
- Belser UC, Grutter L, Vailati F, Bornstein MM, Weber HP, Buser D. Outcome evaluation of early placed maxillary anterior single-tooth implants using objective esthetic criteria: a cross-sectional, retrospective study in 45 patients with a 2- to 4-year follow-up using pink and white esthetic scores. *J Periodontol* 2009;80(1):140-51
- Belser UC, Schmid B, Higginbottom F, Buser D. Outcome analysis of implant restorations located in the anterior maxilla: a review of the recent literature. *Int J Oral Maxillofac Implants* 2004;19 Suppl:30-42.
- Bengazi F, Wennstrom JL, Lekholm U. Recession of the soft tissue margin at oral implants. A 2-year longitudinal prospective study. *Clin Oral Implants Res* 1996;7:303-310.

Botos S, Yousef H, Zweig B, Flinton R, Weiner S. The effects of laser microtexturing of the dental implant collar on crestal bone levels and peri-implant health. *Int J Oral Maxillofac Implants* 2011;26(3):492-498.

Broggini N, McManus LM, Hermann JS, Medina R, Schenk RK, Buser D, Cochran DL. Peri-implant inflammation defined by the implant-abutment interface. *J Dent Res* 2006;85(5):473-478.

Brunette DM, Chehroudi. The effects of the surface topography of micromachined titanium substrata on cell behavior in vitro and in vivo. *J Biomech Eng* 1999;121(1): 49-57.

Buser D, Bornstein MM, Weber HP, Grutter L, Schmid G, Belser UC. Early implant placement with simultaneous guided bone regeneration following single-tooth extraction in the esthetic zone: a cross-sectional, retrospective study in 45 subjects with a 2- to 4-year follow-up. *J Periodontol* 2008;79:1773-1781.

Buser D, Chen ST, Weber HP, Belser UC. Early implant placement following single-tooth extraction in the esthetic zone: biologic rationale and surgical procedures. *Int J Periodontics Restorative Dent* 2008;28(5):441-451.

Buser D, Martin W, Belser UC. Optimizing esthetics for implant restorations in the anterior maxilla: anatomic and surgical considerations. *Int J Oral Maxillofac Implants* 2004;19 Suppl:43-61.

Buser D, Mericske-Stern R, Bernard JP, Behneke A, Behneke N, Hirt HP, Belser UC, Lang NP. Long-term evaluation of non-submerged ITI implants. Part 1: 8-year life table analysis of a prospective multi-center study with 2359 implants. *Clin Oral Implants Res* 1997;8:161-172.

Buser D, Weber HP, Lang NP. Tissue integration of non-submerged implants. 1-year results of a prospective study with 100 ITI hollow-cylinder and hollow-screw implants. *Clin Oral Implants Res* 1990;1(1):33-40.

Buser D, Wittneben J, Bornstein MM, Grutter L, Chappuis V, Belser UC. Stability of contour augmentation and esthetic outcomes of implant-supported single crowns in the esthetic zone: 3-year results of a prospective study with early implant placement postextraction. *J Periodontol* 2011;82(3):342-349.

Canullo L, Fedele GR, Iannello G, Jepson S. Platform switching and marginal bone-level alterations: the results of a randomized-controlled trial. *Clin Oral Implants Res* 2010;21(1):115-121.

Canullo L, Iurlaro G, Iannello G. Double-blind randomized controlled trial study on post-extraction immediately restored implants using the switching platform concept: soft tissue response. preliminary report. *Clin Oral Implants Res* 2009;20(4):414-420.

Canullo L, Rasperini G. Preservation of peri-implant soft and hard tissues using platform switching of implants placed in immediate extraction sockets: a proof-of-concept study with 12- to 36-month follow-up. *Int J Oral Maxillofac Implants* 2007;22:995-1000.

Cappiello M, Luongo R, Di Iorio D, Bugea, Cocchetto R, Celletti R. Evaluation of peri-implant bone loss around platform-switched implants. *Int J Periodontics Restorative Dent* 2008;28:347-355.

Cardaropoli G, Lekholm U, Wennstrom JL. Tissue alterations at implant-supported single-tooth replacements: a 1-year prospective clinical study. *Clin Oral Implants Res* 2006;17:165-171.

Castellon P, Casadaban M, Block MS. Techniques to facilitate provisionalization of implant restorations. *J Oral Maxillofac Surg* 2005;63(9):72-79.

Chang M, Wennstrom JL, Odman P, Andersson B. Implant supported single-tooth replacements compared to contralateral natural teeth. Crown and soft tissue dimensions. *Clin Oral Implants Res* 1999;10:185-194.

Cho H, Jang H, Kim D, Park J, Kim H, Choi S, Kim C, Kim B. The effects of interproximal distance between roots on the existence of interdental papillae according to the distance from the contact point to the alveolar crest. *J Periodontol* 2006;77(10):1651-1657.

Choquet V, Hermans M, Adriaenssens P, Daelemans P, Tarnow DP, Malevez C. Clinical and radiographic evaluation of the papilla level adjacent to single-tooth dental implants. A retrospective study in the maxillary anterior region. *J Periodontol* 2001;72:1364-1371.

Chow YC, Wang HL. Factors and techniques influencing peri-implant papillae. *Implant Dent* 2010;19(3):208-219.

Chung S, Rungcharassaeng K, Kan JY, Roe P, Lozada JL. Immediate single tooth replacement with subepithelial connective tissue graft using platform switching implants: a case series. *J Oral Implantol* 2011;37(5):559-569.

Cochran DL, Hermann JS, Schenck R, Higginbottom F, Buser D. Biologic width around titanium implants. A histometric analysis of the implanto-gingival junction around unloaded and loaded nonsubmerged implants in the canine mandible. *J Periodontol* 1997;68:186-198.

Cooper LF, Ellner S, Moriarty J, Felton DA, Paquette D, Molina A, Chaffee N, Asplund P, Smith R, Hostner C. Three-year evaluation of single-tooth implants restored 3 weeks after 1-stage surgery. *Int J Oral Maxillofac Implants* 2007;22:791-800.

Cornelini R. Connective tissue grafts in postextraction implants with immediate restoration: a prospective controlled clinical study. *Pract Periodontics Aesthet Dent* 2008;20(6):337-343.

Cosyn J, Eghbali A, De Bruyn H, Collys K, Cleymaet R, De Rouck T. Immediate single-tooth implants in the anterior maxilla: 3-year results of a case series on hard and soft tissue response and aesthetics. *J Clin Periodontol* 2011;38(8):746-753.

Davarpanah M, Martinez H, Etienne D, Zabalegui I, Mattout P, Chiche F, Michel JF. A prospective multicenter evaluation of 1,583 3i implants: 1- to 5-year data. *Int J Oral Maxillofac Implants* 2002;17:820-828.

David R. Provisional resoration for an osseointegrated single maxillary anterior implant. *J Can Dent Assoc* 2008;74(7):609-612.

De Bruyn H, Atashkadeh M, Cosyn J, van de Velde T. Clinical outcome and bone preservation of single titanium implants installed with flapless or flap surgery. *Clin Implant Dent Relat Res* 2011;13(3):175-183.

De Rouck T, Collys K, Cosyn J. Single-tooth replacement in the anterior maxilla by means of immediate implantation and provisionalization: A review. *Int J Oral Maxillofac Implants* 2008;23:897-904.

De Rouck T, Collys K, Wyn I, Cosyn J. Instant provisionalization of immediate single-tooth implants is essential to optimize esthetic treatment outcomes. *Clin Oral Implants Res* 2009;20:566-570.

Degidi M, Nardi D, Piattelli A. Peri-implant tissue and radiographic bone levels in the immediately restored single-tooth implant: a retrospective analysis. *J Periodontol* 2008;79:252-259.

Degidi M, Novaes AB, Nardi D, Piattelli A. Outcome analysis of immediately placed, immediately restored implants in the esthetic area: the clinical relevance of different interimplant distances. *J Periodontol* 2008;79:1056-1061.

Degidi M, Piattelli A, Gehrke P, Carinci F. Clinical outcome of 802 immediately loaded 2-stage submerged implants with a new grit-blasted and acid-etched surface: 12 month follow-up. *Int J Oral Maxillofac Implants* 2006;21:763-768.

Eckfeldt A, Carlsson GE, Borjesson G. Clinical evaluation of single-tooth restorations supported by osseointegrated implants: a retrospective study. *Int J Oral Maxillofac Implants* 1994;9:179-183.

Engquist B, Nilson H, Astrand P. Single-tooth replacement by osseointegrated Branemark implants. A retrospective study of 82 implants. *Clin Oral Implants Res* 1995;6(4):238-245.

Engquist B, Nilson H, Astrand P. Single-tooth replacement by osseointegrated branemark implants. a retrospective study of 82 implants. *Clin Oral Implants Res* 1995;6(4):238-245.

Evans CD, Chen ST. Esthetic outcomes of immediate implant placements. *Clin Oral Implants Res* 2008;19:73-80.

Gallucci GO, Grutter L, Chuang SK, Belser UC. Dimensional changes of peri-implant soft tissue over 2 years with single-implant crowns in the anterior maxilla. *J Clin Periodontol* 2011;26(1):293-299.

Gargiulo AW, Wentz FM, Oraban B. Dimensions and relations of the dentogingival junction in humans. *J Periodontol* 1961;32(3):261-267.

Gastaldo JF, Cury PR, Sendyk WR. Effect of the vertical and horizontal distances between adjacent implants and between a tooth and an implant on the incidence of interproximal papilla. *J Periodontol* 2004;75:1242-1246.

Giannopoulou C, Bernard J, Buser D, Carrel A, Belser UC. Effect of intracrevicular restoration margins on peri-implant health: clinical, biochemical, and microbiologic findings around esthetic implants up to 9 years. *Int J Oral Maxillofac Implants* 2003;18:173-181.

Gomez-Roman G. Influence of flap design on peri-implant interproximal crestal bone loss around single-tooth implants. *Int J Oral Maxillofac Implants* 2001;16:61-67.

Goodacre CJ, Bernal G, Rungcharassaeng K, Kan JY. Clinical complications with implants and implant prostheses. *J Prosthet Dent* 2003;90(2):70-71.

Goodacre CJ, Kan JY, Rungcharassaeng K. Clinical complications of osseointegrated implants *J Prosthet Dent* 1999;8(5):537-552.

Gotfredsen K. A 5-year prospective study of single-tooth replacements supported by the Astra Tech® implant: A pilot study. *Clin Implant Dent Relat Res* 2004;6(1):1-8.

Grunder U. Stability of the mucosal topography around single-tooth implants and adjacent teeth: 1-year results. *Int J Periodontics Restorative Dent* 2000;20:11-17.

Grunder U, Gracis S, Capelli M. Influence of the 3-D bone-to-implant relationship on esthetics. *Int J Periodontics Restorative Dent* 2005;25:113-119.

Grunder U, Polizzi G, Goene R, Hatano N, Henry P, Jackson WJ, Kawamura K, Kohler S, Renouard F, Rosenberg R, Triplett G, Werbit M, Lithner B. A 3-year prospective multicenter follow-up report on the immediate and delayed-immediate placement of implants. *Int J Oral Maxillofac Implants* 1999;14:210-216.

Grutter L, Belser UC. Implant loading protocols for the partially edentulous esthetic zone. *Int J Oral Maxillofac Implants* 2009;24 Suppl:169-179.

Haas R, Polak C, Furhauser R, Mailath-Pokorny G, Dortbudak O, Watzek G. A long-term follow-up of 76 Branemark single-tooth implants. *Clin Oral Implants Res* 2002;13:38-43.

Hall JA, Payne AG, Purton DG, Torr B, Duncan WJ, De Silva RK. Immediately restored, single-tapered implants in the anterior maxilla: prosthodontic and aesthetic outcomes after 1 year. *Clin Implant Dent Relat Res* 2007;9(1):34-45.

Henry PJ, Laney WR, Jemt T, Harris D, Krogh PH, Polizzi G, Zarb GA, Herrmann I. Osseointegrated implants for single-tooth replacement: a prospective 5-year multicenter study. *Int J Oral Maxillofac Implants* 1996;11:450-455.

Henry PJ, Laney WR, Jemt T, Harris D, Krogh PH, Polizzi G, Zarb GA, Herrmann I. Osseointegrated implants for single-tooth replacement: a prospective 5-year multicenter study. *Int J Oral Maxillofac Implants* 1996;11(4):450-455.

Hermann JS, Buser D, Schenk RK, Cochran DL. Crestal bone changes around titanium implants. a histometric evaluation of unloaded non-submerged and submerged implants in the canine mandible. *J Periodontol* 2000;71(9):1412-1424.

Hermann JS, Buser D, Schenk RK, Schoolfield JD, Cochran DL. Biologic width around one- and two-piece titanium implants. A histometric evaluation of unloaded nonsubmerged and submerged implants in the canine mandible. *Clin Oral Implants Res* 2001;12:559-571.

Hermann JS, Cochran DL, Nummikoski PV, Buser D. Crestal bone changes around titanium implants. A radiographic evaluation of unloaded nonsubmerged and submerged implants in the canine mandible. *J Periodontol* 1997;68:1117-1130.

Jemt T. Regeneration of gingival papillae after single-implant treatment. *Int J Periodontics Restorative Dent* 1997;17:327-333.

Jemt T. Restoring the gingival contour by means of provisional resin crowns after single-implant treatment. *Int J Periodontics Restorative Dent* 1999;19:21-29.

Jemt T, Ahlberg G, Henriksson K, Bondevik O. Changes of anterior clinical crown height in patients provided with single-implant restorations after more than 15 years of follow-up. *Int J Prosthodont* 2006;19(5):455-461.

Jemt T, Laney WR, Harris D, Henry PJ, Krogh PH, Polizzi G, Zarb GA, Herrmann I. Osseointegrated implants for single tooth replacement: A 1-year report from a multicenter prospective study. *Int J Oral Maxillofac Implants* 1991;6:29-36.

Jemt T, Pettersson P. A 3-year follow-up study on single implant treatment. *J Dent* 1993;21:203-208.

Jemt T, Pettersson P. A 3-year follow-up study on single implant treatment. *J Dent* 1993;21(4):203-208.

Kan JY, Rungcharassaeng K, Liddel G, Henry P, Goodacre CJ. Periimplant tissue response following immediate provisional restoration of scalloped implants in the esthetic zone: A one-year pilot prospective multicenter study. *J Prosthet Dent* 2007;97:S109-S118.

Kan JY, Rungcharassaeng K, Lozada J. Immediate placement and provisionalization of maxillary anterior single implants: 1-year prospective study. *Int J Oral Maxillofac Implants* 2003a;18:31-39.

Kan JY, Rungcharassaeng K, Morimoto T. Facial gingival tissue stability after connective tissue graft with single immediate tooth replacement in the esthetic zone: Consecutive case report. *J Oral Maxillofac Surg* 2009;76:40-48.

Kan JY, Rungcharassaeng K, Umezu K, Kois JC. Dimensions of peri-implant mucosa: an evaluation of maxillary anterior single implants in humans. *J Periodontol* 2003b;74:557-562.

Kan JYK, Rungcharassaeng K, Lozada JL, Zimmerman G. Facial gingival tissue stability following immediate placement and provisionalization of maxillary anterior single implants: a 2- to 8-year follow-up. *Int J Oral Maxillofac Implants* 2011;26(1):179-187.

Karlsson U, Gotfredsen K, Olsson C. Single-tooth replacement by osseointegrated Astra Tech dental implants: a 2 year report. *Int J Prosthodont* 1997;10(4):318-324.

Kawai ES, Almeida AL. Evaluation of the presence or absence of papilla between tooth and implant. *Cleft Palate Craniofac J* 2008;45(4):399-406.

Kemppainen P, Eskola S, Ylipaavalniemi P. A comparative prospective clinical study of two single-tooth implants: a preliminary report of 102 implants. *J Prosthet Dent* 1997;77:382-387.

Khayat PG, Milliez SN. Prospective clinical evaluation of 835 multithreaded tapered screw-vent implants: Results after two years of functional loading. *J Oral Implantol* 2007;33(4):225-231.

Kim B, Kim Y, Yun P, Yi Y, Lee H, Kim S, Son J. *Oral Surg Oral Med Oral Pathol Oral Radiol Endod* 2009;107:24-28

Koh RU, Oh TJ, Rudek I, Neiva GF, Misch CE, Rothman ED, Wang HL. Hard and soft tissue changes after crestal and subcrestal immediate implant placement. *J Periodontol* 2011;82(8):1112-1120.

Kois JC. Altering gingival levels: The restorative connection. Part I: Biologic variables. *J Esthet Dent* 1994;6(1):3-9.

Kois JC. Predictable single tooth peri-implant esthetics: Five diagnostic keys. *Compend Contin Educ Dent* 2001;22(3):199-206.

Kois JC, Kan JY. Predictable peri-implant gingival aesthetic: surgical and prosthodontic rationales. *Pract Proced Aesthet Dent* 2001;13(9):691-698.

Laney WR, Jemt T, Harris D, Henry PJ, Krogh PH, Polizzi G, Zarb GA, Herrmann I. Osseointegrated implants for single-tooth replacement: Progress report from a multicenter prospective study after 3 years. *Int J Oral Maxillofac Implants* 1994;9:49-54.

Laney WR, Jemt T, Harris D, Henry PJ, Krogh PH, Polizzi G, Zarb GA, Herrmann I. Osseointegrated implants for single-tooth replacement: progress report from a multicenter prospective study after 3 years. *Int J Oral Maxillofac Implants* 1994;9(1):49-54.

Lazzara RJ, Porter SS. Platform switching: a new concept in implant dentistry for controlling postrestorative crestal bone levels. *Int J Periodontics Restorative Dent* 2006;26(1):9-17.

Lee D, Park K, Moon I. Dimensions of interproximal soft tissue between adjacent implants in two distinctive implant systems. *J Periodontol* 2006;77:1080-1084.

Levin L, Pathael S, Dolev E, Schwartz-Arad D. Aesthetic versus surgical success of single dental implants: 1- to 9-year follow-up. *Pract Proced Aesthet Dent* 2005;17(8):533-538.

Levine RA, Clem DS, Wilson T, Higginbottom F, Solnit G. Multicenter retrospective analysis of the ITI implant system used for single-tooth replacements: Results of loading for 2 or more years. *Int J Oral Maxillofac Implants* 1999;14:516-520.

Levine RA, Clem DS, Wilson TG, Higginbottom F, Saunders SL. A multicenter retrospective analysis of the ITI implant system used for single-tooth replacements: Preliminary results at 6 or more months of loading. *Int J Oral Maxillofac Implants* 1997;12:237-242.

London RM. The esthetic effects of implant platform selection. *Compend Contin Educ Dent* 2001;22(8):675-682.

Lops D, Chiapasco M, Rossi A, Bressan E, Romeo E. Incidence of inter-proximal papilla between a tooth and an adjacent immediate implant placed into a fresh extraction socket: 1-year prospective study. *Clin Oral Implants Res* 2008;19:1135-1140.

Lops D, Mosca D, Muller A, Rossi A, Rozza R, Romeo E. Management of peri-implant soft tissues between tooth and adjacent immediate implant placed into fresh extraction single socket: a one-year prospective study on two different types of implant-abutment connection design. *Minerva Stomatol* 2011;60(9):403-415.

Melevez C, Hermans M, Daelemans P. Marginal bone levels at Branemark system implants used for single tooth restoration. The influence of implant design and anatomical region. *Clin Oral Implants Res* 1996;7(2):162-169.

Moberg L, Kondell P, Kullman L, Heimdahl A, Gynther GW. Evaluation of single-tooth restorations on ITI dental implants. A prospective study of 29 patients. *Clin Oral Implants Res* 1999;10:45-53.

Morris HF, Ochi S. Influence of two different approaches to reporting implant survival outcomes for five different prosthodontic applications. *Ann Periodontol* 2000;5(1):129-136.

Naert I, Koutsikakis G, Duyck J, Quiryen M, Jacobs R, van steenberghe D. Biologic outcome of implant-supported restorations in the treatment of partial edentulism. part 1: a longitudinal clinical evaluation. *Clin Oral Implants Res* 2002;13:381-389.

Nemcovsky CE, Moses O, Artzi Z. Interproximal papillae reconstruction in maxillary implants. *J Periodontol* 2000;71:308-314.

Nevins M, Camelo M, Nevins ML, Schupbach P, Kim DM. Connective tissue attachment to laser-microgrooved abutments: a human histologic case report. *Int J Periodontics Restorative Dent* 2012;32(4):385-392.

Nevins M, Kim DM, Jun SH, Guze K, Schupbach P, Nevins ML. Histologic evidence of a connective tissue attachment to laser microgrooved abutments: a canine study. *Int J Periodontics Restorative Dent* 2010;30(3):245-255.

Nevins M, Nevins ML, Camelo M, Boyesen JL, Kim DM. Human histologic evidence of a connective tissue attachment to a dental implant. *Int J Periodontics Restorative Dent* 2008;28(2):111-121.

Nevis M, Nevis ML, camelo M, Boyesen JL, Kim DM. Human histologic evidence of a connective tissue attachment to a dental implant. *Int J Periodontics Restorative Dent* 2008;28:111-121.

Nisapakultorn K, Suphanantachat S, Silkosessak O, Rattanamongkolgul S. Factors affecting soft tissue level around anterior maxillary single-tooth implants. *Clin Oral Implants Res* 2010;21(6):662-670.

Norton MR. The Astra Tech single-tooth implant system: A report on 27 consecutively placed and restored implants. *Int J Periodontics Restorative Dent* 1997;17:575-583.

Oates TW, West J, Jones J, Kaiser D, Cochran DL. Long-term changes in soft tissue height on the facial surface of dental implants. *Implant Dent* 2002;11(3):272-276.

Ochsenbein C, Ross S. A reevaluation of osseous surgery. *Dent Clin North Am* 1969;13(1):87-102.

Olsson M, Lindhe J. Periodontal characteristics in individuals with varying form of the upper central incisors. *J Clin Periodontol* 1991;18:78-82.

Olsson M, Lindhe J, Marinello CP. On the relationship between crown form and clinical features of the gingiva in adolescents. *J Clin Periodontol* 1993;20:570-577.

Palattella P, Torsello F, Cordaro L. Two-year prospective clinical comparison of immediate replacement vs. immediate restoration of single tooth in the esthetic zone. *Clin Oral Implants Res* 2008;19:1148-1153.

Palmer RM, Palmer PJ, Smith BJ. A 5-year prospective study of Astra single tooth implants. *Clin Oral Implants Res* 2000;11(2):179-182.

Palmer RM, Palmer PL, Newton T. Dealing with esthetic demands in the anterior maxilla. *Periodontol* 2000 2003;33:105-118.

Palmer RM, Smith BJ, Palmer PJ, Floyd PD. A prospective study of Astra single tooth implants. *Clin Oral Implants Res* 1997;8:173-179.

Park JB. Healing of extraction socket grafted with deproteinized bovine bone and acellular dermal matrix: histomorphometric evaluation. *Implant Dent* 2010;19(4):307-313.

Park JB. Immediate implantation with ridge augmentation using acellular dermal matrix and deproteinized bovine bone: a case report. *J Oral Implantol* 2011;37(6):717-721.

Patel K, Marda N, Donos N. Radiographic and clinical outcomes of implants placed in ridge preserved sites: a 12-month post-loading follow-up. *Clin Oral Implants Res* 2012;epub:1-7.

Penarrocha-Oltra D, Demarchi CL, Maestre-Ferrin L, Penarrocha-Diago M, Penarrocha-Diago M. Comparison of immediate and delayed implants in the maxillary molar region:

a retrospective study of 123 implants. *Int J Oral Maxillofac Implants* 2012;27(3):604-610.

Priest G. Single-tooth implants and their role in preserving remaining teeth: A 10-year survival study. *Int J Oral Maxillofac Implants* 1999;14:181-188.

Priest G. Predictability of soft tissue form around single-tooth implant restorations. *Int J Periodontics Restorative Dent* 2003;23:19-27.

Priest G. Developing optimal tissue profiles implant-level provisional restorations. *Dent Today* 2005;24(11):96-100.

Raes F, Cosyn J, Crommelinck E, Coessens P, De Bruyn H. Immediate and conventional single implant treatment in the anterior maxilla: 1-year results of a case series on hard and soft tissue response and aesthetics. *J Clin Periodontol* 2011;38(4):385-394.

Ribeiro FS, Pontes AE, Marcantonio E, Piattelli A, Neto RJ, Marcantonio E. Success rate of immediate nonfunctional loaded single-tooth implants: immediate versus delayed implantation. *Implant Dent* 2008;17(1):109-117.

Romanos GE, Traini T, Johansson CB, Piattelli A. Biologic width and morphologic characteristics of soft tissues around immediately loaded implants: studies performed on human autopsy specimens. *J Periodontol* 2010;81(1):70-78.

Romeo E, Chiapasco M, Ghisolfi M, Vogel G. Long-term clinical effectiveness of oral implants in the treatment of partial edentulism. Seven year life table analysis of a prospective study with ITI® Dental Implant system used for single-tooth restorations. *Clin Oral Implants Res* 2002;13:133-143.

Romeo E, Lops D, Rossi A, Storelli S, Rozza R, Chiapasco M. Surgical and prosthetic management of interproximal region with single-implant restorations: 1-year prospective study. *J Periodontol* 2008;79:1048-1055.

Roos J, Sennerby L, Lekholm U, Jemt T, Grondahl K, Albrektsson T. A qualitative and quantitative method for evaluating implant success: a 5-year retrospective analysis of the Branemark implant. *Int J Oral Maxillofac Implants* 1997;12:504-514.

Rosenberg ES, Torosian J. An evaluation of differences and similarities observed in fixture failure of five distinct implant systems. *Pract Periodontics Aesthet Dent* 1998;10(6):687-698.

Ryser MR, Block MS, Mercante DE. Correlation of papilla to crestal bone levels around single tooth implants in immediate or delayed crown protocols. *J Oral Maxillofac Surg* 2005;63:1184-1195.

Saadoun AP. The key to peri-implant esthetics: hard- and soft-tissue management. *Dent Update* 1997;8(6):41-46.

Salama H, Salama MA, Garber D, Adar P. The interproximal height of bone: a guidepost to predictable aesthetic strategies and soft tissue contours in anterior tooth replacement. *Pract Periodontics Aesthet Dent* 1998;10(9): 1131-41.

Sanavi F, Weisgold A, Rose L. Biologic width and its relation to periodontal biotypes. *J Esthet Dent* 1998;10(3):157-163.

Santosa RE. Provisional restoration options in implant dentistry. *Aust Dent J* 2007;52(3):234-242.

Scheller H, Urgell JP, Kultje C, Klineberg I, Goldberg PV, Stevenson-Moore P, Alonso JM, Schaller M, Corria RM, Engquist B, Toreskog S, Kastenbaum F, Smith CR. A 5-year multicenter study on implant-supported single crown restorations. *Int J Oral Maxillofac Implants* 1998;13:212-218

Schmitt A, Zarb GA. The longitudinal clinical effectiveness of osseointegrated dental implants for single-tooth replacement. *Int J Prosthodont* 1993;6:197-202.

Schneider D, Grunder U, Ender A, Hammerle CHF, Jung RE. Volume gain and stability of peri-implant tissue following bone and soft tissue augmentation: 1-year results from a prospective cohort study. *Clin Oral Implants Res* 2011;22(1):28-37.

Scholander S. A retrospective evaluation of 259 single-tooth replacements by the use of Branemark implants. *Int J Prosthodont* 1999;12:483-491.

Schropp L, Isidor F. Clinical outcome and patient satisfaction following full-flap elevation for early and delayed placement of single-tooth implants: A 5-year randomized study. *Int J Oral Maxillofac Implants* 2008;23:733-743.

Schropp L, Isidor F, Kostopoulos L, Wenzel A. Interproximal papilla levels following early versus delayed placement of single-tooth implants: A controlled clinical trial. *Int J Oral Maxillofac Implants* 2005;20:753-761.

Schropp L, Kostopoulos L, Wenzel A, Isidor F. Clinical and radiographic performance of delayed-immediate single-tooth implant placement associated with peri-implant bone defects. A 2-year prospective, controlled, randomized follow-up report. *J Clin Periodontol* 2005;32:480-487.

Silness J, Loe H. Periodontal disease in pregnancy. II. Correlation between oral hygiene and periodontal condition. *Acta Odontol Scand* 1964;22(1):121-135.

Small PN, Tarnow DP. Gingival recession around implants: A 1-year longitudinal prospective study. *Int J Oral Maxillofac Implants* 2000;15:527-532.

Small PN, Tarnow DP, Cho SC. Gingival recession around wide-diameter versus standard-diameter implants: A 3 to 5 year longitudinal prospective study. *Pract Proced Aesthet Dent* 2001;13(2):143-146.

Smith DE, Zarb GA. Criteria for success of osseointegrated endosseous implants. *J Prosthet Dent* 1989;62(5):567-572.

Spray JR, Black CG, Morris HF, Ochi S. The influence of bone thickness on facial marginal bone response: stage 1 placement through stage 2 uncovering. *Ann Periodontol* 2000;5(1):119-128.

Tarnow DP, Cho SC, Wallace SS. The effect of inter-implant distance on the height of inter-implant bone crest. *J Periodontol* 2000;71:546-549.

Tarnow DP, Elian N, Fletcher P, Froum S, Magner A, Cho SC, Salama M, Salama H, Garber DA. Vertical distance from the crest of bone to the height of the interproximal papilla between adjacent implants. *J Periodontol* 2003;74:1785-1788.

Tarnow DP, Eskow RN. Considerations for single-unit esthetic implant restorations. *Compend Contin Educ Dent* 1995;16(8):780-784.

Tarnow DP, Eskow RN. Preservation of implant esthetics: soft tissue and restorative considerations. *J Esthet Dent* 1996;8(1):12-19

Tarnow DP, Magner AW, Fletcher P. The effect of the distance from the contact point to the crest of bone on the presence or absence of the interproximal papilla. *J Periodontol* 1992;63:995-996.

Thilander B, Odman J, Jemt T. Single implants in the upper incisor region and their relationship to the adjacent teeth. *Clin Oral Implants Res* 1999;10:346-355.

Tsuda H, Rungcharassaeng K, Kan JY, Roe P, Lozada JL, Zimmerman G. Peri-implant tissue response following connective tissue and bone grafting in conjunction with immediate single-tooth replacement in the esthetic zone: a case series. *Int J Oral Maxillofac Implants* 2011;26(2):427-436.

Valentini P, Abensur D, Albertini JF, Rocchesani M. Immediate provisionalization of single extraction-site implants in the esthetic zone: a clinical evaluation. *Int J Periodontics Restorative Dent* 2010;30(1):41-51.

van Steenberghe D, De Mars G, Quirynen M, Jacobs R, Naert I. A prospective split-mouth comparative study of two screw-shaped self-tapping pure titanium implant systems. *Clin Oral Implants Res* 2000;11:202-209.

Walther W, Klemke J, Worle M, Heners M. Implant-supported single-tooth replacements: risk of implant and prosthesis failure. *J Oral Implantol* 1996;22(3-4):236-239.

Weber HP, Kim DM, Ng MW, Hwang JW, Fiorellini JP. Peri-implant soft tissue health surrounding cement- and screw-retained implant restorations: a multi-center, 3-year prospective study. *Clin Oral Implants Res* 2006;17:375-379.

Weiner S, Simon J, Ehrenberg DS, Zxeig B, Ricci JL. The effects of laser microtextured collars upon crestal bone levels of dental implants *Implant Dent* 2008;17:217-228.

Wheeler R. Wheeler R (ed. 5) *Dental Anatomy Physiology, and Occlusion*. Philadelphia, W. B. Sanders Company, 1974. Book 1974;124-126.

Wheeler SL. Eight-year clinical retrospective study of titanium plasma-sprayed and hydroxyapatite-coated cylinder implants. *Int J Oral Maxillofac Implants* 1996;11:340-350.

Wiesner G, Esposito M, Worthington H, Schlee M. Connective tissue grafts for thickening peri-implant tissues at implant placement. one-year results from an explanatory split-mouth randomized controlled clinical trial. *Int J Oral Implantol* 2010;3(1):27-35.

Woodyard JG, Greenwell H, Hill M, Drisko C, Iasella JM, Scheetz J. The clinical effect of acellular dermal matrix on gingival thickness and root coverage compared to coronally positioned flap alone. *J Periodontol* 2004; 75(1): 44-56.

Wyatt CC, Zarb GA. Treatment outcomes of patients with implant-supported fixed partial prostheses. *Int J Oral Maxillofac Implants* 1998;13:204-211.

Yan JJ, Tsai AY, Wong MY, Hou LT. Comparison of acellular dermal graft and palatal autograft in the reconstruction of keratinized gingiva around dental implants: a case report. *Int J Periodontics Restorative Dent* 2006;26(3):287-292.

Zigdon H, Machtei EE. The dimensions of keratinized mucosa around implants affect clinical and immunological parameters. *Clin Oral Implants Res* 2008;19:387-392.

Zitzmann NU, Scharer P, Marinello CP. Long-term results of implants treated with guided bone regeneration: a 5 year prospective study. *Int J Oral Maxillofac Implants* 2001;16:355-366.

Appendix A

The Plaque Index

(Silness J, L e H. Periodontal disease in pregnancy. II. Correlation between oral hygiene and periodontal condition. Acta Odontol Scand 1964; 22(1): 121-135.

The plaque index of Silness and Loe (1964) will be measured. Scores will be as follows:

0 - No plaque

1 - A film of plaque adhering to the free gingival margin and adjacent area of the tooth.

The plaque may be seen in situ only after application of disclosing solution or by using the probe on the tooth surface.

2 - Moderate accumulation of soft deposits within the gingival pocket, or on the tooth and gingival margin which can be seen with the naked eye.

3 - Abundance of soft matter within the gingival pocket and/or on the tooth and gingival margin.

Each gingival unit (buccal, lingual, mesiobuccal, distobuccal, mesiolingual, and distolingual) of the individual tooth will be given a score from 0-3, called the plaque index for the area. The scores from the 6 areas of the tooth are added and divided by 6 to give the plaque index for the tooth.

Appendix B

The Gingival Index

(Lobene R, Weatherford T, Ross W, et al. A modified gingival indices for use in clinical trials. Clin Prev Dent 1986; 8(1): 3-6.

The Gingival Index (Lobene et al. 1986) will be measured. Scores will be as follows:

- 0 - Normal gingiva
- 1 - Mild inflammation - slight change in color, slight edema
- 2 - Moderate inflammation - redness, edema, and glazing.
- 3 - Severe inflammation - marked redness and edema. Ulceration.

Each gingival unit (buccal, lingual, mesiobuccal, distobuccal, mesiolingual, and distolingual) of the individual tooth will be given a score from 0-3, called the gingival index for the area. The scores from the 6 areas of the tooth are added and divided by 6 to give the gingival index for the tooth.

Appendix C

Tooth Mobility

(Laster L, Laudenschlager K, Stoller N. An evaluation of clinical mobility measurements. J Periodontol 1975; 46(10): 603-607.

Miller proposed the following tooth mobility index:

- 0 - Movability of the crown within normal physiologic limits.
- 1 - Movability of the crown up to 0.5 mm in one direction. Does not exceed 1.0 mm in both directions.
- 2 - Movability of the crown from 0.5 to 1 mm in one direction. Does not exceed 2.0 mm in both directions.
- 3 - Movability of the crown exceeding 1 mm in one direction and/or vertical depressibility. Greater than 2.0 mm in both directions and/or vertical depressibility.

The index that will be used in the study is a modification of Miller's index (Laster et al., 1975) where half scores are used. Thus scores of 0, 0.5, 1, 1.5, 2, 2.5, and 3 will be utilized.

Appendix D

Standardized Radiographic Technique

An occlusal stent is used to provide a stable foundation for the radiograph holder. The stent is placed on a cast and the Rinn radiograph holder is positioned to allow as near as possible paralleling technique. They are constructed using Regisil® PB™ Plaster Bite Registration Paster and a Rinn-XCP on the patient model. Radiographs will be taken at baseline, pre-implant placement, immediately post-implant placement, 2 months, 4 months and 6 months post-implant placement.

Appendix E

Periodontal Form

(Kois JC: Altering gingival levels: the restorative connection part I: biologic variables. J Esthet Dent 1994; 6(1): 3-9.

Kois found the following average measurements for categories of periodontal form:

High: A distance of greater than 5 mm exists from the midfacial free gingival margin to a periodontal probe positioned horizontally at the most coronal tip of the interproximal papilla.

Normal: A distance of 4 to 5 mm exists from the midfacial free gingival margin to a periodontal probe positioned horizontally at the most coronal tip of the interproximal papilla.

Flat: A distance of less than 4 mm exists from the midfacial free gingival margin to a periodontal probe positioned horizontally at the most coronal tip of the interproximal papilla.

Pronounced scalloped, scalloped, and flat will be substituted for High, normal, and flat, respectively in the study.

Appendix F

Periodontal Biotype

A UNC periodontal probe will be inserted into the gingival sulcus of the facial tooth surface. If the probe is not visible through the facial gingival, a thick biotype will be assigned. If only the black color of the probe markings are visible, a moderate biotype will be assigned. If the millimeter markings on the probe are completely visible through the tissues the biotype will be designated as thin.

Appendix G

Papilla Harmony

A line will be extrapolated that is perpendicular to the midline of the maxillary arch. If corresponding papilla tips are located at the same point with reference to this line, papillae will be considered harmonious. If the papillae are not located at the same point, papillae will not be considered harmonious, and the discrepancy will be measured.

Appendix H

Gingival Margin Harmony

If the gingival margin is even with adjacent teeth, it will be considered harmonious. If the gingival margin is not even adjacent teeth, it will not be considered harmonious, and the discrepancy will be measured.

Appendix I

Subjective Evaluation of Implant Placement

Buccal-lingual placement: Buccal, Optimal, or Lingual.

Incisal-apical placement: Incisal, Optimal, or Apical.

Mesial-distal placement: Mesial, Optimal, or Distal.

Appendix J

Bone Quality

(Lekholm U, Zarb G, Albrektsson T. Tissue integrated prosthesis: Osseointegration in clinical dentistry. Quintessence 1985: 199-205.

1. Almost the entire jaw is comprised of homogeneous compact bone.
2. A thick layer of compact bone surrounds a core of dense trabecular bone.
3. A thin layer of cortical bone surrounds a core of dense trabecular bone of favorable strength.
4. A thin layer of cortical bone surrounds a core of low density trabecular bone.

Appendix K

Pink Esthetic Score

(Furhauser et al. Evaluation of soft tissue around single-tooth implant crowns: The pink esthetic score. Clin Oral Implants Res 16(6): 639-644, 2005.)

Seven variables are assessed with a score of 2, 1, or 0 with 2 being the best and 0 being the worst with the highest possible score attainable being 14 (score of 2 x 7 variables).

Variables	0	1	2
Mesial Papilla	Absent	Incomplete	Present
Distal Papilla	Absent	Incomplete	Present
Level of Soft Tissue Margin	Major Discrepancy > 2mm	Minor Discrepancy 1-2 mm	No Discrepancy < 1mm
Soft-Tissue Contour	Unnatural	Fairly Natural	Natural
Alveolar Process	Obvious	Slight	None
Soft-Tissue Color	Obvious Difference	Moderate Difference	No Difference
Soft-Tissue Texture	Obvious Difference	Moderate Difference	No Difference

Appendix L

White Esthetic Score

(Belser et al. Outcome evaluation of early placed maxillary anterior single-tooth implants using objective esthetic criteria: A cross-sectional, retrospective study in 45 patients with a 2- to 4-year follow-up using pink and white esthetic scores. J Periodontol; 80(1): 140-151, 2009.)

Five variables are assessed with a score of 2, 1, or 0 with 2 being the best and 0 being the worst with the highest possible score attainable being 10 (score of 2 x 5 variables).

Variables	0	1	2
Tooth form	Major Discrepancy	Minor Discrepancy	No Discrepancy
Tooth volume/outline	Major Discrepancy	Minor Discrepancy	No Discrepancy
Color (hue/value)	Major Discrepancy	Minor Discrepancy	No Discrepancy
Surface texture	Major Discrepancy	Minor Discrepancy	No Discrepancy
Translucency	Major Discrepancy	Minor Discrepancy	No Discrepancy

Appendix M

Jemt Papilla Index Scoring System

(Jemt T. Regeneration of gingival papillae after single-implant treatment. Int J Periodontics Restorative Dent 17(4): 326-333, 1997.)

The mesial and distal papillae were each given a score of 0 to 4.

Score 0	No papilla is present.
Score 1	Less than half the papilla is present
Score 2	At least half of the papilla is present but the papilla tip does not extend to the interproximal contact point.
Score 3	Papilla completely fills the embrasure space and is harmonious with the adjacent papilla.
Score 4	The papilla is overfilling the embrasure and covering the adjacent crown.

Appendix N

1. I am pleased with the appearance of my implant tooth compared to the surrounding teeth.

0 _____ 100

2. I am pleased with the appearance of the gums around my implant tooth.

0 _____ 100

3. Overall, I am pleased with the appearance of my implant tooth.

0 _____ 100

Appendix O

Examiner calibration: Probing measurements only.

The data will be compared from indices or measurements taken by the examiner on three different patients at two different times within a 60 minute period to measure the inter examiner accuracy and reproducibility.

1. A minimum of three subjects are to be recruited to participate in the calibration. The subjects should exhibit a range of the criteria being assessed in the index or measurements being performed (i.e., subjects with moderate to severe periodontal disease).
2. The examiner will score 6 teeth per subject within the same quadrant.
3. The examiner will measure each subject, calling out the measurements, site by site, while the assistant records. The subjects will not eat or brush their teeth between scorings.
4. Duplicate measurements of the subjects will be taken within 60 minutes following the initial measurements. The assistant will record the second set of data.
5. The examiner will not compare the two sets of data at any time during the calibration. The examiner will not discuss their measurements with the assistant or the subject during the calibration.
6. The assistant recording the data will be responsible for handling the data sheets. The examiner will have no access to any of the data sheets during the course of the calibration.

8. The data sets will be analyzed for percent agreement. Acceptable percent agreement will reflect the limits set for the different parameters measured.
9. Acceptable percent agreement will be: 90% w/in ± 1 mm for probing depth, recession and attachment level and 70% within 0 mm.

CURRICULUM VITAE

Thomas L. Peterson

Birth Date: September 10, 1980

Place: Fort Worth, TX

Education:

- **MS** University of Louisville
2009 – 2012 Masters in Oral Biology
- **Certificate in Periodontics** University of Louisville
2009 – 2012
- **DMD** Georgia Health Sciences University,
2005 – 2009 Augusta, GA
School of Dentistry
- **BA** University of Georgia, Athens, GA
1999-2003
- **High School:** Stratford Academy, Macon, GA
- American Academy of Periodontology meeting 2012
- Academy of Osseointegration meeting 2011.
- Internal Medicine Rotation, University of Louisville Hospital. May 2010.
- Anesthesiology Rotation, University of Louisville Hospital. June 2010
- Waterlase Course Certification August 2009

Academic Accomplishments:

- Winner of 1st place in the clinical research category of the 2012 Billy Pannel competition at Southern Academy Periodontology.

- American Association of Periodontology dental student award for outstanding achievements in periodontics (2009)
- Successful completion of National Board Part I and II.
- Successful completion of the Central Regional Dental Testing Service.

Professional Affiliations:

- American Academy of Periodontology 2011 – present.
- Academy of Osseointegration – 2011 – present.
- American Dental Association 2005 – present.

Public Health/Volunteer Experience:

- Member of the Give a Smile committee (2007-2009).
- Weekend volunteer screening patients at the local flea market (2005-2008).

Research Experience:

- The Effect of Implant Placement and Simultaneous Soft Tissue Augmentation in the esthetic Zone Using Either Connective Tissue Autograft or Acellular Dermal Matrix Allograft on Peri-implant Hard and Soft Tissue Healing. (Master's degree research: A randomized controlled blinded clinical trial.)
- Co-investigator for Ridge Preservation Comparing the Clinical and Histologic Healing of an Intra-socket Mineralized Cancellous Allograft vs. an Intra-socket Mineralized Cancellous Allograft Plus a Facial Overlay Bovine Xenograft with a Bioabsorbable Barrier. A randomized controlled blinded clinical trial.

Employment Experience:

- Dental assistant for Dr. Richard B. Liipfert in Macon, GA for 18 months. 2004-2005.
- Orthodontic assistant for Dr. Robert Edenfield in Macon, GA for 10 months. 2003-2004.